

Accuracy of Plain Radiographs Versus 3D Analysis of Ankle Stress Test

Eve Hoffman, BA; David Paller, MS; Sarath Koruprolu, MS; Mark Drakos, MD; Steve B. Behrens, MD; Joseph J. Crisco, PhD;
Christopher W. DiGiovanni, MD
Providence, RI

ABSTRACT

Background: Radiographic stress testing using both the anterior drawer (AD) and talar tilt (TT) technique is a widely accepted means of assessing ankle instability. The purpose of this study was to investigate the accuracy of plain film radiography in measuring translation of the talus during the AD test and the rotation of the talus during TT stress testing. In addition to determining the true accuracy of radiologic assessment in two planes, our goal was to further define instability in the sagittal, coronal and transverse planes. **Methods:** Twenty lower extremity specimens were placed in a Telos ankle stress apparatus, and respective lateral and AP radiographs were taken during simulated AD and TT testing. Positional measurements were calculated from the films. Next, a three-dimensional tracking system was used to calculate these displacements. The anterior talofibular ligament and calcaneofibular ligament were sectioned to simulate an unstable ankle, followed by repeat measurement using both methods. Movement calculated using the three dimensional system was compared to that of plain radiographs using a paired t-test. **Results:** Mean positional changes determined by plain film radiographs were found to be significantly lower than those calculated by the three-dimensional system in both AD and TT tests in the intact and sectioned states ($p < 0.001$). **Conclusion:** Radiographic stress testing assessment of ankle instability appears to be much less accurate than previously believed. **Clinical Relevance:** Compared to values calculated with the 3D system, radiographic measurements may underestimate the true magnitude of TT and AD changes which could influence clinical decision making.

Key Words: Radiograph; Stress Testing; Instability; Three Dimensional; 3D

INTRODUCTION

Ankle sprains are the most common musculoskeletal injury, accounting for about two million emergency department visits annually.¹¹ Most sprains involve the lateral ligament complex which includes the anterior talofibular ligament (ATFL), calcaneofibular ligament (CFL) and the posterior talofibular ligament (PTFL). In an ankle sprain, one or more of these ligaments are typically injured due to an inversion type mechanism on a plantarflexed foot. This can subsequently cause damage to ankle proprioception and a decrease in ankle stability.^{4,8}

Most acute lateral ligament injuries do not result in any permanent sequelae, and can be treated successfully with rehabilitation and bracing alone. However, the rate of persistent pain and instability has been reported to approach approximately 10% to 30% of cases.⁵ An acute ankle injury may lead to healing of the ankle ligaments in an elongated position and increased laxity of the ankle. The diagnosis of chronic ankle instability is possible when repetitive sprains or persistent symptoms of “giving way” are present. Ankle pain, swelling and weakness may also present as clinical findings.⁹

The degree of laxity of the lateral ligaments can be clinically assessed in patients with chronic ankle instability with anterior drawer and talar tilt tests. However, these tests are often clinician and experience dependent, and there can be differences in inter-observer reliability. Many surgeons rely on stress radiography as a more objective means of confirming mechanical ankle instability. Radiographic evaluation using both the anterior drawer (AD) and talar tilt (TT) tests has become a widely accepted technique to assess the degree of ankle laxity.⁶ The anterior drawer test is employed to measure anterior displacement of the talus in relation to the tibia while an anterior force is applied to sublux the talus from the tibia. The talar tilt test measures

No benefits in any form have been received or will be received from a commercial party related directly or indirectly to the subject of this article.

Corresponding Author:
Eve Hoffman, BA
Warren Alpert Medical School
Brown University
Coro West, Suite 404
1 Hoppin Street
Providence, RI 02903
E-mail: eve_hoffman@brown.edu

For information on pricings and availability of reprints, call 410-494-4994, x232.

the angle between the tibial plafond and the talar dome as an inversion force is applied to the calcaneus.⁷ It has been suggested that an AD of more than 10 mm or a 5-mm difference between the injured and uninjured ankle is a sign of instability. Similarly, a TT of more than 10 degrees or a 5 degree difference between ankles also indicates ankle instability. With corroborating clinical exams, stress radiographs that exceed these laxity levels are routinely indicated for surgical intervention.⁷

Despite their widespread use, stress radiographs have their limitations. The ankle joint in part resembles a saddle joint, and thus what could be perceived as motion in a single plane likely represents more complex, coupled motions. In other words, standard AD and TT stress radiographs may be a two-dimensional assessment of a three-dimensional problem. Furthermore, talar morphology is complex, and taking measurements in relation to this curved structure by plain radiography oversimplifies the anatomy and may lead to further inaccuracy.

The purpose of this study was to evaluate the reliability of radiographic measurements of talar translation during AD testing and talar angular rotation during TT testing. The AD and TT tests were performed on a cadaveric model in the intact state and after transection of the ATFL and CFL. To evaluate any difference, we compared these radiographic measurements to values obtained with a three-dimensional motion tracking system. In addition to determining the true accuracy of radiologic assessment in two planes, our goal was to further define instability in the sagittal, coronal and transverse planes.

MATERIALS AND METHODS

Twenty lower extremity cadaver specimens (from the proximal tibia to the toes) were obtained from ten cadavers (mean, 40 ± 12 years). These matched pairs were screened for gross anatomical defects and pre-existing ankle laxity, and placed in a freezer at -20°C until 24 hours prior to testing. Measurement of AD translation and TT angle was performed on the specimens using both two-dimensional radiographs and the three-dimensional system in the intact state. Then a lateral incision was made along the fibula. The ATFL and CFL origins were identified.

The ATFL and the CFL were both sectioned along their origins on the fibula distally to the level of the peroneal tendons. This was performed to simulate an unstable ankle and the measurements were repeated.

To measure AD translation and TT angle using radiographs, specimens were placed in a Telos ankle stress apparatus, (Telos, Hungen, Germany) at neutral ankle dorsiflexion (Figure 1). Radiographs were taken from a lateral view (sagittal plane) in an unloaded condition, and then repeated after a 1.7 N-m load was applied to simulate the AD test. The shortest distance between the posterior edge of the tibia and the talar dome was measured in both

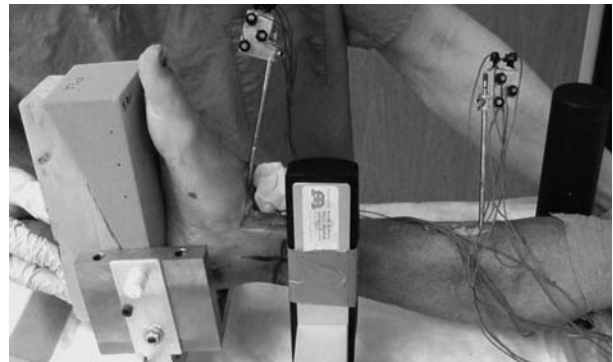


Fig. 1: Specimen loaded into the Telos machine, and affixed with Optotrak sensor system.

conditions, and the difference in translation between the loaded and the unloaded state was calculated (Figure 2, A and B).⁷ Following this, radiographs were taken from an anterior-posterior view (coronal plane) in an unloaded condition, and repeated after a 1.7 N-m load was applied to simulate the TT test. The angle between the inferior edge of the tibia and the superior edge of the talus was compared to determine the angular difference between the two states (Figure 2, C and D). Care was taken to ensure that radiographs of the ankle were performed in the same planes. To ensure this, the lateral radiographs were taken with a perfect overlap of the talar dome to ensure repeatability. Similarly, the AP radiographs were taken with the same amount of tibia-fibula overlap to avoid inaccuracy due to rotation.

The same specimens were then used to calculate AD translation and TT angles using the Optotrak System (Optotrak 3020, NDI, Waterloo, Canada), which tracked the movements of the rigidly affixed sensors in three-dimensional space. Each specimen was instrumented with two Steinman pins of equal diameter by the same fellowship trained foot and ankle surgeon, and each flag of markers was affixed to its respective Steinman pin using the same orientation for all specimens. The tibial pins were placed bicortically in an anterior to posterior direction. The talar pins were placed unicortically in an oblique direction along the longitudinal plane of the talar neck. The talar pin was oriented in such a manner in that it would not impinge on the tibia, navicular or other structures of the foot when dorsiflexed, plantarflexed, inverted, everted or internally or externally rotated. A rigid orientation between flag, pin, and bone facilitated motion tracking of the two bones of interest, namely the talus and tibia.

In all specimens, the same markers and flags were used to analyze motion. Prior to motion analysis, however, the two rigid bodies (tibia and talus with respective flag and pin) were localized in each specimen with the three-dimensional measurement system, and thereafter calibrated. The location of each sensor in three-dimensional space was tracked using

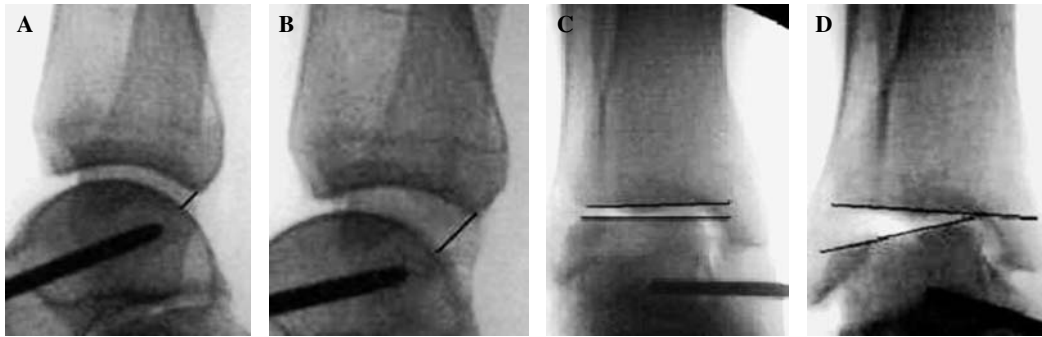


Fig. 2: Radiographs showing the measurements made to calculate anterior drawer and talar tilt: unstressed anterior drawer (A), stressed anterior drawer (B), unstressed talar tilt (C), and stressed talar tilt (D).

the Optotrak camera system and First Principles software (NDI, Waterloo, Canada) in the unloaded condition as well as in the loaded condition for both the AD and TT test. The location of each sensor in the unloaded state was then compared to the location in the loaded state to determine the change in position of the talus and the tibia during the test.

To determine if the measurements obtained with plain film radiographs differed significantly from the measurements obtained with the 3D motion tracking system the AD translation and TT angular values were each compared independently using a paired t-test. Measurements calculated from the plain films were compared to both the total magnitude of displacement calculated by the Optotrak as well as the in plane displacement (sagittal plane for AD and coronal plane for TT) calculated from the Optotrak. In all cases, statistical significance was set to $p \leq 0.05$ *a priori*.

RESULTS

During AD testing, radiographic measure of translation was significantly less than the total magnitude of three-dimensional translation identified in both the intact and sectioned state ($p < 0.001$ for both). The mean translation value in the intact state was 3.7 ± 1.9 mm using the radiograph, and 5.8 ± 2.1 mm using the Optotrak system. The mean translational value in the sectioned state was 8.6 ± 2.8 mm using the radiograph and 12.7 ± 3.6 mm using the Optotrak (Table 1). There were also statistically significant differences between the radiographic measurements and those made by the Optotrak in the sagittal translation plane only for both the intact ($p = 0.037$) and sectioned tests ($p = 131$ 0.023) (Table 2).

Radiographic measurements of the TT testing were also significantly lower than those using the three-dimensional measurements in both the intact and sectioned state ($p < 0.001$ for both). In the intact state the mean value for tibio-talar angle was 6.1 ± 4.1 degrees using the radiographs and was 20.1 ± 10.1 degrees using the Optotrak. In the sectioned state the mean tibio-talar angle was 18.6 ± 4.6 degrees

Table 1: Mean (± 1 SD) Measurements Made by Radiograph and by the Optotrak

	Radiographic Measurements	Optotrak Measurements
	Translation Magnitude	Translation Magnitude
Intact Anterior Drawer	3.7 ± 1.9 mm	5.8 ± 2.1 mm
Cut Anterior Drawer	8.6 ± 2.8 mm	12.7 ± 3.6 mm
	Rotation RMS	Rotation RMS
Intact Talar Tilt	$6.1 \pm 4.1^\circ$	$20.1 \pm 10.1^\circ$
Cut Talar Tilt	$18.6 \pm 4.6^\circ$	$31.3 \pm 7.2^\circ$

using the radiographs and 31.3 ± 7.2 degrees using the Optotrak (Table 1). There was also a statistically significant difference between the radiographic measurements and the measurements made by the Optotrak in the coronal plane only for both the intact ($p < 0.001$) and sectioned tests ($p = 0.005$) (Table 2).

DISCUSSION

The purpose of this study was to investigate the accuracy of plain film radiography in measuring translation of the talus during the AD test and the rotation of the talus during TT stress testing. Our findings indicated that the radiographic measurements were consistently and statistically lower than values calculated using the Optotrak system. These data suggest that perhaps plain radiography may not adequately identify coupled or out of plane motion of the ankle joint, and that perhaps some patients with borderline or even normal AD and TT plain film radiographic results who are

Table 2: Mean (± 1 SD) Three-Dimensional Movement of the Talus Calculated by the Optotrak

	Lateral/Medial Translation	Posterior/Anterior Translation	Tension/Compression	In Plane Magnitude	Translation Magnitude
Intact Anterior Drawer	0.7 \pm 3.8 mm	-4.2 \pm 2.1 mm	-0.3 \pm 1.5 mm	4.5 \pm 2.1 mm	5.8 \pm 2.1 mm
Cut Anterior Drawer	1.1 \pm 7.8 mm	-9.3 \pm 2.3 mm	-1.4 \pm 4.6 mm	10.3 \pm 2.0 mm	12.7 \pm 3.6 mm
	In Plane Translations				
	Out of Plane Translation	External/Internal Rotation	Inversion/Eversion	In plane Magnitude	Rotation RMS
	Out of Plane Rotations				
Intact Talar Tilt	-13.3 \pm 12.2°	-0.8 \pm 7.7°	9.5 \pm 6.1°	9.5 \pm 6.1°	20.1 \pm 10.1°
Cut Talar Tilt	-19.8 \pm 6.0°	1.5 \pm 8.9°	22.0 \pm 6.4°	22.0 \pm 6.4°	31.3 \pm 7.2*

*Positive Values are defined as lateral translation, posterior translation, tension, dorsiflexion, inversion, and external rotation. Negative values are defined as medial translation, anterior translation, compression, plantarflexion, eversion and internal rotation.

considered to be functionally unstable may indeed actually instead be mechanically unstable. Previous studies of ankle kinematics have reported that motion of the ankle joint rarely occurs in a single plane, since the talocrural and the subtalar joints have oblique axes of rotation.² Thus, when measuring AD and TT, the motion of the talus relative to the tibia is not simple sagittal plane translation and coronal plane inversion. The Optotrak measured movement in all three planes for both tests. In addition, sectioning of the ATFL and CFL increased the magnitude of the motion in all planes for both the AD and TT tests.

For the AD test, the data show that after sectioning the ATFL and CFL, the movement of the talus relative to the tibia was greater for anterior translation, as well as for lateral translation and compression. For TT, the magnitude of inversion increased after sectioning the lateral ligaments, as did the magnitude of motion towards plantarflexion. These multiplanar motions make it difficult, if not impossible, to accurately measure displacements from a two-dimensional radiograph.²

It is also noteworthy that we found plain film radiographs to consistently underestimate the displacement and angular values that were calculated in three dimensions, and the Optotrak measurements in a single plane more accurately approximated the measurements compared to radiographs. This finding suggests that plain radiographs may lead clinicians to underestimate translation and tilt angles when evaluating ankle instability because displacement and angular cutoffs for surgery are based on two-dimensional measurements rather than true motion.

In addition to the inability of plain film radiographs to accurately measure three-dimensional, coupled motion, several studies have identified other sources of error in measurements made from plain film radiographs. Ray et al., for example, compared two different methods of measuring displacement of the tibia and talus from a plain film radiograph during AD. One method used concentric circles to measure the distance between the central point of the tibial and talar articular surfaces. The other method, which was also used in this study, calculated the distance between the posterior margin of the articular surface of the tibia and the closest point on the talar dome. Significantly different displacements were found between the two methods, reinforcing the idea that measurements from radiographs are not reliably reproducible.⁸

Another group of studies found that obtaining a reproducible measurement of any parameter in the ankle is difficult because of the inability to precisely reposition the ankle with respect to the X-ray.^{1,10} Since the calculations in our study were based on measurements obtained from radiographs of ankles in an unloaded condition which were subsequently compared to radiographs of the ankle with a force applied to simulate the AD and TT tests, the errors found in repeated radiographic studies may have been a factor in our results. This same error may also be present in clinical settings where

similar comparisons are made between multiple radiographs. However, calculations performed with the three-dimensional Optotrak system were found to have repeatability within 0.66 millimeters for AD and 0.04 degrees for TT.

Another limitation of this study is that it used a cadaveric model to approximate the movements of patients during AD and TT stress testing. The study also approximated ankle instability by sectioning of the ATFL and CFL ligaments. These constraints may limit our ability to generalize the results to a wider patient population. Finally, this study made an assumption that the 3D Optotrak system was the gold standard in measurement of ankle motion. Although we have not compared this system to other systems measuring movement in three dimensions, the Optotrak 3020 system used in this study has a validated RMS accuracy of 0.1 mm, and a three-dimensional resolution to 0.01 mm.³

Our study suggests that the use of plain film radiographs is not as accurate as a three-dimensional method of measuring movement of the ankle and may simply be a projection of the displacement vector of an unstable ankle. The probability of underestimating displacements of the ankle complex due to coupled and out of plane motion is high. However, because they are widely available, relatively inexpensive, and non-invasive, they continue to have widespread use and play a role in surgical indications. If clinicians are to continue the use of stress radiographs for the assessment of chronic ankle laxity, it should be noted that the measurements obtained may not only be unreliable with significant inter and intra- observer discrepancies, but also likely underestimate the true instability of the joint. These shortcomings should be considered when using strict cut-offs for the surgical indication of ankle instability. Despite our findings, currently we are unaware of an alternative method for measuring the degree of ankle instability in clinical practice. We do not propose altering the presently accepted parameters. However, future enhancements in markerless computer tomography methods may provide valuable data for the way we determine instability clinically.

CONCLUSION

Three-dimensional analysis of ankle motion does provide a more accurate and reliable tool to assess ankle stability. Such a method may be used to evaluate the biomechanics and efficacy of various ankle stabilization procedures. Further investigation between 3D analysis and plain radiographs may provide further correlation between these values so that assessment of ankle stability and the criteria for instability become more clearly defined.

ACKNOWLEDGMENTS

The authors would like to thank Alison Biercevicz.

REFERENCES

1. **Beumer, A; vanHemert, WLW; Niesing, R; et al.:** Radiographic measurement of the distal tibiofibular syndesmosis has limited use. *Clin Orthop Relat Res.* **423**:227–234, 2004. <http://dx.doi.org/10.1097/01.blo.0000129152.81015.ad>
2. **Beynon, BD; Webb, G; Huber, BM; et al.:** Radiographic measurement of anterior talar translation in the ankle: determination of the most reliable method. *Clin Biomech.* **20**:301–306, 2005. <http://dx.doi.org/10.1016/j.clinbiomech.2004.11.011>
3. **Crisco, JJ; Fujita, L; Spencer, DB:** The dynamic flexion/extension properties of the lumbar spine in vitro using a novel pendulum system. *J Biomech.* **40**:2767–2773, 2007. <http://dx.doi.org/10.1016/j.jbiomech.2006.12.013>
4. **deVries, JS; Kingma, I; Blankevoort, L; vanDijk, CN:** Difference in balance measures between patients with chronic ankle instability and patients after an acute ankle inversion trauma. *Knee Surg Sports Traumatol Arthrosc.* **18**:601–606, 2010. <http://dx.doi.org/10.1007/s00167-010-1097-1>
5. **Hubbard, TJ; Kramer, LC; Denegar, CR; Hertel, J:** Contributing factors to chronic ankle instability. *Foot Ankle Int.* **3**:343–354, 2007. <http://dx.doi.org/10.3113/FAI.2007.0343>
6. **Johannsen, A:** Radiological diagnosis of lateral ligament lesion of the ankle. *Acta Orthi.* **49**:295–301, 1978. <http://dx.doi.org/10.3109/17453677809005768>
7. **Marder, RA:** Current methods for the evaluation of ankle ligament injuries. *Instructional. J Bone Joint Surg Am.* **76-A**:1103–1111, 1994.
8. **Ray, RG; Christensen, JC; Gusman, DN:** Critical evaluation of anterior drawer measurement method in the ankle. *Clin Orthop Relat Res.* **334**:215–224, 1997. <http://dx.doi.org/10.1097/00003086-199701000-00028>
9. **Safran, MR; Benedetti, RS; Bartolozzi, AR; Mandelbaum, BR:** Lateral ankle sprains: a comprehensive review Part I: etiology, pathoanatomy, histopathogenesis, and diagnosis. *Med Sci Sport and Ex.* **31**:S429–S437, 1999. <http://dx.doi.org/10.1097/00005768-199907001-00004>
10. **Tochigi, Y; Suh, JS; Amendola, A; Pedersen, DR; Saltzman, CL:** Ankle alignment on lateral radiographs: part 1: sensitivity of measures to perturbances of ankle positioning. *Foot Ankle Int.* **27**:82–87, 2006.
11. **Vitellas, KM; Mueller, CF; Blau, NA; Verner, JJ; Zuelzer, WA:** The role of stress radiographs for the severe ankle sprain: a 7-year prospective study. *Emerg Radiol.* **2**:339–344, 1995. <http://dx.doi.org/10.1007/BF02615897>