

# Outcomes of Isolated Type II SLAP Lesions Treated With Arthroscopic Fixation Using a Bioabsorbable Tack

David B. Cohen, M.D., Struan Coleman, M.D., Ph.D. Mark C. Drakos, M.D.,  
Answorth A. Allen, M.D., Stephen J. O'Brien, M.D., David W. Altchek, M.D., and  
Russell F. Warren, M.D.

---

**Purpose:** The objective was to clinically evaluate the treatment of type II Slap lesions repaired surgically using a bioabsorbable device. **Type of Study:** Retrospective clinical follow-up study. **Methods:** Forty-one patients with isolated type II SLAP lesions who were treated with arthroscopic fixation were identified. Patients were excluded for rotator cuff tears, instability, or subacromial decompression. Patients completed the L'Insalata and the American Society of Shoulder and Elbow Surgeons (ASES) questionnaires, and underwent a thorough shoulder examination at a minimum of 2 years postoperatively. **Results:** At a mean of 3.7 years follow-up, 33 of 41 patients returned for physical examination and 6 others returned the L'Insalata questionnaire. The mean L'Insalata and ASES scores were 86.7 and 86.8, respectively; 27 patients reported their satisfaction as good to excellent but only 14 of the 29 athletes returned to their preinjury level of athletics. The average ASES scores were statistically different in patients who had their rotator cuff pierced versus those who did not ( $P < .05$ ). In addition, 13 of 16 patients who experienced night pain had a cuff piercing approach. **Conclusions:** Despite high outcome scores, overall patient satisfaction was only 71%. In addition, up to 41% continued to experience some degree of night pain. Patients treated with a rotator cuff piercing had a significantly poorer outcome. Moreover, the patients who were athletes performed poorer on their outcomes evaluation than did their nonathletic counterparts. Whereas the outcome scores overall were high, this problem is still difficult to treat successfully. This may be because of the high demands of athletes. The data also suggest that placing portals through the rotator cuff may be associated with poorer surgical outcomes. **Level of Evidence:** Level III. **Key Words:** Shoulder—Labrum—SLAP lesion—SureTac.

---

Injuries to the superior labrum–biceps tendon complex were initially described by Andrews et al.<sup>1</sup> in their report on biceps tendon injuries in a population of throwing athletes. They noted that the anterosuperior portion of the glenoid labrum could be lifted off the glenoid by a pull from the biceps tendon. In 1990,

Snyder et al.<sup>2</sup> coined the term “SLAP” lesion describing the superior-labral anterior posterior lesion. The type II lesion, the focus of this study, results when the labrum and biceps anchor are detached from their insertion on the superior glenoid.

However, when the biceps-labral complex is unstable, as in type II and IV lesions, surgical repair is preferred. There have been unsuccessful outcomes with debridement alone for type II SLAP lesions.<sup>3-5</sup> As a result, several techniques have been used to repair the biceps-labral complex to the glenoid. These include arthroscopic suture anchors, staples, metal screws, transosseous suture, and bioabsorbable implants.<sup>5-9</sup>

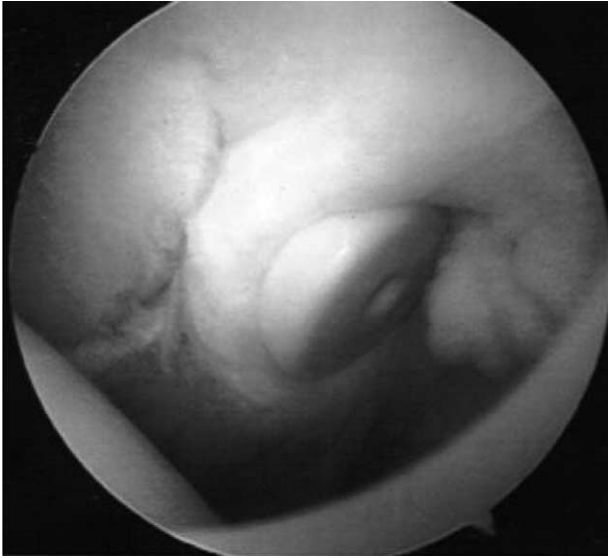Few studies, however, have examined the results of

---

*From the Sports Medicine and Shoulder Service, Hospital for Special Surgery Cornell Medical Center, New York, New York, U.S.A.*

*Address correspondence and reprint requests to Mark Drakos, M.D., Hospital for Special Surgery, 535 East 71st St, New York, NY 10021, U.S.A. E-mail: drakosm@hss.edu*

*© 2006 by the Arthroscopy Association of North America  
0749-8063/06/2202-4281\$32.00/0  
doi:10.1016/j.arthro.2005.11.002*



**FIGURE 1.** Arthroscopic view of a superoposterior labrum lesion fixated with the SureTac device.

these treatments. Those available involve limited numbers, limited follow-up (less than 2 years), and in all cases focus on populations with mixed labral pathologies or combined procedures. In part, this is because of the high frequency with which labral injuries involve associated pathology. As a result, it has been difficult to understand the impact that the labral tear has on a patient's future. This is the only study we are aware of that has identified and assessed a population of patients with an "isolated" type II SLAP lesion (no additional pathology) who underwent no additional procedures other than arthroscopic bioabsorbable tack fixation of the superior labrum to the glenoid. By focusing on this isolated subset of labral injuries, we hope to better elucidate the surgical outcomes both subjectively and objectively to more accurately guide patient and physician expectations when addressing this particular lesion.

## METHODS

The authors reviewed the charts of 860 patients treated arthroscopically for any labral pathology at our institution between 1992 and 1998 by 4 surgeons. One hundred forty of these patients had arthroscopically documented superior labral lesions treated with debridement and/or tack fixation (Fig 1). These lesions included types I, II, III, and IV SLAP lesions as well as concomitant pathologies such as rotator cuff tears, Bankart lesions, and capsular laxity. Of these, 41 had

isolated type II SLAP lesions treated with arthroscopic bioabsorbable tack fixation. All lesions were diagnosed by clinical examination and magnetic resonance imaging evaluation, which was confirmed at arthroscopy. A type II SLAP lesion was defined as any lesion of the superior half of the labrum that destabilized the biceps anchor and did not extend into the substance of the biceps tendon. Patients who had previously undergone any ipsilateral shoulder surgery, concomitant rotator cuff repair, stabilization, or subacromial decompression (bursectomy or acromioplasty) were excluded from our study. Therefore, this study examined only isolated type II SLAP lesions treated with arthroscopic stabilization using a bioabsorbable device. Follow-up was obtained on 39 of the 41 eligible patients. Thirty-three out of the 41 eligible patients (80%) were brought back to our institution for a thorough physical examination and were administered the L'Insalata and the American Society of Shoulder and Elbow Surgeons (ASES) questionnaires.<sup>10,11</sup> Six patients were unable to return for a physical examination because of travel considerations, but did complete the L'Insalata questionnaires. One patient died before the follow-up and we were unable to locate another.

The mean age of the 39 patients at surgery was 34 years (range, 16 to 56 years); there were 37 male and 2 female patients. Twenty-eight patients had surgery on their dominant shoulders, 8 patients were throwing athletes (6 pitchers, 2 fielders), and 21 patients were nonthrowing athletes (football, lacrosse, hockey, skiing, volleyball, soccer).

Nineteen patients could identify an acute injury to the shoulder, 15 of which were sports related. Twenty patients complained of chronically symptomatic shoulders, 14 of which involved athletics. Before surgery, all 39 patients complained of shoulder pain. Other symptoms in order of frequency were clicking or locking, pain with overhead activities, and weakness. The active compression test was positive in all 25 patients on whom the test was performed.<sup>12</sup> Arthroscopic tack placement was performed using a portal that penetrated only the rotator interval in 16 or a portal that penetrated the rotator cuff in 23 patients.

## Operative Technique

Arthroscopic surgery of the shoulder was performed under interscalene block anesthesia with the patients in the beach-chair position. A standard arthroscopic examination was performed through a posterior portal that was placed 3-cm inferior and 1-cm medial to the posterolateral corner of the acromion. The superior

labrum was carefully probed from an anterior portal created in the rotator interval using a needle localization technique. Particular attention was given to the undersurface of the labrum at its junction with the glenoid. Superior labral laxity can be difficult to differentiate from a labral tear. We attempted to classify the labrum shape as “meniscal” or “nonmeniscal” and its attachment as “edge” or “recessed” with articular cartilage over the glenoid. Evaluation included direct observation of the attachment using a probe for elevation. The presence of a tear at the labral edge or recessed site with apparent laxity and detachment of the biceps insertion was an indication for repair. The undersurface of the rotator cuff, the long head of the biceps brachii tendon, the articular surfaces, and the remainder of the labrum were also assessed. Only lesions that had an unstable biceps-labral complex were repaired. Lesions with extension into the long head of the biceps tendon were excluded from our study.

The superior portion of the glenoid neck was debrided to bleeding bone using an arthroscopic shaver, rasp, or burr. Depending on surgeon preference and the location of labral pathology, instruments were placed either through a superolateral rotator interval portal or through a trans-rotator cuff portal, penetrating either the supraspinatus or infraspinatus muscle-tendon junctions.<sup>13</sup> The SLAP lesions were stabilized using between 1 and 4 bioabsorbable tacks (SureTac, Acufex Microsurgical, Mansfield, MA) using a previously described technique, in all cases.<sup>13</sup> Twenty patients required 1 tack, 14 had 2 tacks, 4 had 3, and 1 had 4 tacks. The tack is cannulated and constructed of polyglyconate (Maxon), a synthetic copolymer that dissolves over time by hydrolysis alone, requiring no active or passive degradative or inflammatory response by the host's tissues. The stabilized labrum was then probed to determine its stability and additional tacks were added as needed.

### Postoperative Care

All patients were immobilized in internal rotation for 4 weeks postoperatively. Pendulum and elbow range-of-motion exercises were encouraged during this period. At 4 weeks, shoulder motion was increased using active-assisted and passive techniques. Resistance exercises were initiated when full motion was achieved. At 4 months, the patients were permitted to begin light throwing and underhand racquet sports. After 6 months, contact sports, unrestricted activity, and throwing were permitted.

### Complications

One patient required reoperation 2 months after his initial repair. This patient failed to comply with postoperative sling immobilization and lifting restrictions, leading to failed fixation 9 days postoperatively (3% reoperation rate). There were no other complications including wound infection and tack synovitis.

### Follow-up

Patients were evaluated using the L'Insalata Shoulder Rating questionnaire to address patient's perceived outcomes, the ASES evaluation form (subjective and objective assessment), and a thorough physical examination including the active compression test.<sup>11</sup> Minimum follow-up time was 2 years. The mean follow-up was 44 months (range, 25 to 97 months).

Thirty-nine patients completed the L'Insalata Functional Shoulder Rating questionnaire (0-100 points), which assesses pain, activities of daily living, athletics, work, and overall satisfaction. Subjective satisfaction with the results of surgery at follow-up was rated as excellent, good, fair, or poor. Areas for improvement were also recorded. The L'Insalata questionnaire was scored according to the weighted system described by L'Insalata et al.<sup>11</sup> Patients were also questioned whether they had returned to their preinjury level of athletics and whether they felt further surgery on the involved shoulder might be required. Thirty-three patients (80%) underwent a physical examination of the upper extremity to evaluate range of motion, strength, stability, impingement, and the results of the active compression test as described by O'Brien et al.<sup>12</sup> During this examination, the ASES shoulder assessment form, comprising patient self-evaluation and physician assessment components, was completed and scored (0-100 points).

## RESULTS

### Outcome Scores

**L'Insalata Score:** At 2-year minimum follow-up on 39 patients, the average L'Insalata Score was 86.7 points out of a possible 100 (range, 46.1-100 points). Despite this respectable score, only 27 patients (69%) rated their overall satisfaction with the procedure as good or excellent (Fig 2). Seven patients reported a fair result, and 5 rated their result as poor. Among the 29 athletes, only 14 (48%) were able to return to their preinjury level of athletics; 13 (45%) returned in a limited capacity and 2 were unable to play at all.

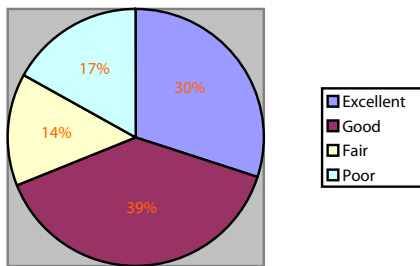


FIGURE 2. The distribution of subjective satisfaction among all the patients who returned L'Insalata questionnaires.

The average L'Insalata score for the nonthrowing athletes was 90.8 with a good-excellent satisfaction rating of 71% compared with a score of 75.9 for the throwers with good-excellent satisfaction of 38% (Fig 3). This difference was significant ( $P < .04$ ). Of the 8 throwing athletes, 3 returned to their preinjury level but 5 returned in only a limited capacity.

Night pain in varying degrees was present in 16 of the 39 patients (41%). Thirteen of these patients had undergone a rotator cuff penetrating approach while only 3 had undergone a rotator interval approach for tack placement. The average L'Insalata score for the group with night pain was 73.9. Twenty-three patients did not experience any night pain and their average score was 95.6.

Among all the patients, when asked to identify the primary area requiring improvement, 21 (54%) cited recreational and athletic activities, 9 patients (23%) pain, and 1 cited daily activities. Seven patients did not feel that any area needed improvement (Fig 4).

**ASES Score:** The mean ASES score for the 33 patients who returned for follow-up was 86.8 points (range, 46.7-100). Pain was rated as absent or mild in

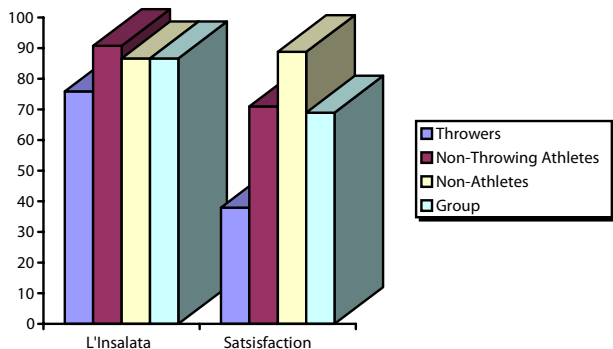


FIGURE 3. The L'Insalata outcome scores and the patient's subjective satisfaction scores based on shoulder demands. (i.e., patient is a thrower, nonthrowing athlete, or nonathlete).

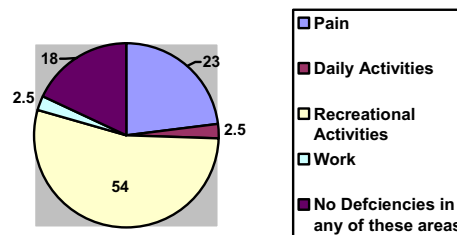


FIGURE 4. The percentages of patients citing particular areas for improvement in shoulder function.

28 patients (85%) and as moderate in 4 (12%) of the patients. However, 10 patients (30%) continued to experience pain at night. All 10 had undergone a cuff-penetrating approach (Fig 5). A positive preoperative O'Brien's Sign (active compression test) converted to negative postoperatively in 21 of 25 (84%) patients who had undergone the test before surgery. A positive postoperative O'Brien's sign correlated highly with low L'Insalata and ASES scores. Impingement signs were present in 7 patients and 2 had positive apprehension tests. Furthermore, a total of 4 patients felt they would require additional shoulder surgery.

**Interval Versus Trans-Rotator Cuff Portal**

We next compared those patients in whom the rotator cuff had been penetrated in performing the procedure with those in whom it had not. The average ASES scores in the rotator-interval portal group compared with the cuff-penetrated group were significantly different: 95 versus 83.3 ( $P < .05$ , Student *t* test). In the interval-portal group, 9 of 11 patients (82%) rated their satisfaction as good-excellent and 2 rated it poor. In the cuff-penetrated group, only 12 of the 22 patients (55%) rated their satisfaction as good-

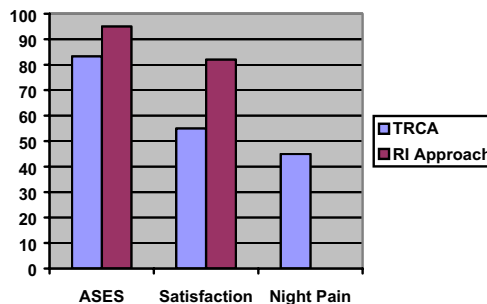


FIGURE 5. The ASES outcome scores, the patient's subjective satisfaction scores, and presence of night pain based on whether the patient had a cuff-penetrating approach or a conventional rotator interval approach.

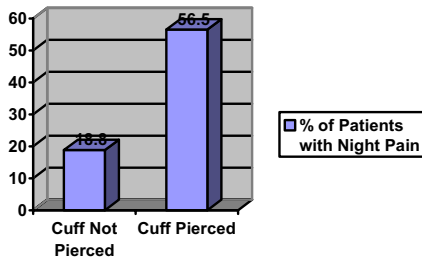


FIGURE 6. The percentage of patients with night pain relative to whether the patient had their rotator cuff penetrated during bioabsorbable tack placement.

excellent, with 7 fair and 3 poor. Of particular note was the finding that all 10 (100%) patients with night pain according to the ASES questionnaire, and 13 of 16 patients noting night pain in the L’Insalata questionnaire had undergone a cuff-penetrating surgical approach (Fig 6).

In an effort to correct for the effect of labral tear size, we compared outcomes among patients whose tears required only a single tack for stabilization with respect to portal placement. The average ASES score for the interval portal group was 95.6 compared with 86.9 in the cuff-penetrated group with good or excellent satisfactions of 88% and 57%, respectively.

**Chronicity**

Patients with acute injuries identified a traumatic event or felt the immediate onset of pain in the setting of a normal shoulder, whereas chronic injuries developed slowly over time with an insidious onset, often in a repetitive task. Chronicity of injury was not a predictor of outcome. Those patients who perceived an acute injury to their shoulder (14 patients) had L’Insalata and ASES scores similar to those with chronic attrition injuries (19 patients) (acute, 86.0 and 88.9; chronic, 84.5 and 84.9).

**Examination**

**Range of Motion:** Range of motion was assessed by measuring forward flexion, external rotation in adduction, external and internal rotation in 90° of abduction, internal rotation, and cross-body adduction. All 33 patients had full forward elevation when compared with the contralateral unaffected shoulder (Fig 7). Only 3 patients (9%) lost external rotation with 2 having minimal losses (<10°) and 1 moderate (<20°). Only 2 patients (6%) lost external rotation with both having minimal losses (<10°). Internal rotation was the most frequently affected plane of motion, with 20 patients out of 33 (61%) having loss of

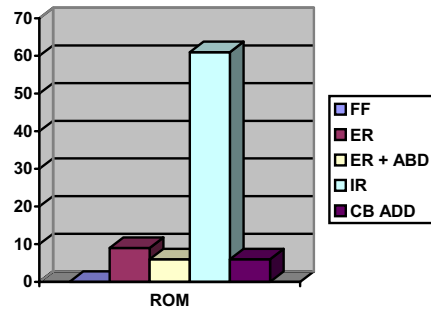


FIGURE 7. The percentages of patients who had a range of motion deficit postoperatively.

at least 1 vertebral level compared with the normal contralateral shoulder, with an average difference of 1.7 levels. Only 2 patients had decreased cross-body adduction measurements with both having moderate losses (<20°).

**Strength:** Strength was evaluated by clinically testing forward elevation, abduction, external rotation, and internal rotation (Fig 8). Of the 33 patients examined, loss of 1 grade in motor strength (4/5) was present in 3 patients (9%) with respect to forward flexion, 4 patients (12%) in resisted abduction, 3 patients in external rotation, and 5 patients in internal rotation. One patient had a loss of 2 grades in strength of internal rotation. Six of these patients (18%) reported that pain limited their effort during strength testing.

Impingement signs were positive in 7 patients (21%). Of these, 4 patients (66%) rated their satisfaction as fair or poor. Three of the 7 patients with evidence of impingement also had a positive O’Brien Sign. Six patients had a positive O’Brien Sign at follow-up. Five of these 6 patients (83%) rated their satisfaction with the procedure as fair or poor. Their

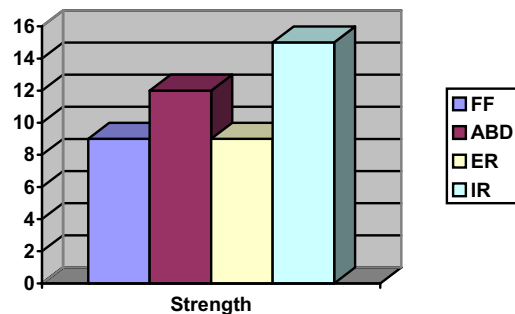


FIGURE 8. The percentage of patients with particular strength deficits postoperatively.

mean L'Insalata and ASES scores were 71.6 and 70.2, respectively.

### Reasons for Failure

Seven patients had impingement at follow-up. This group had a mean L'Insalata score of 77 (*v* 86.7 overall) and good-excellent satisfaction rating of 43% (*v* 69% overall). Five of these 7 patients had undergone a cuff-penetrating approach. None was noted to have evidence of impingement on preoperative examination. In 4 of the 7, the subacromial space was examined at the time of surgery and found to be normal. In the other 3 cases, the subacromial space was not examined. Two patients had instability and both rated their satisfaction poor. One patient retore his labrum during the early postoperative period after not complying with restrictions. Repeat surgery was required and, despite returning to baseball, he remained unsatisfied with his outcome; his L'Insalata score was 53. Failure to return to preinjury level of athletic activity was also identified as a reason for failure (only 40% returned). Two patients cited this as the main reason for poor satisfaction with the procedure despite the fact that they experienced only mild pain overall and had no pathology on physical examination. Finally, the cuff-penetrating surgical approach can be identified as a reason for failure in that it yielded significantly lower scores, satisfaction overall, and accounted for the vast majority of patients who experienced night pain in this study (all 10 patients with night pain according to the ASES questionnaire and 13 of 16 using the L'Insalata questionnaire). No patient experienced tack synovitis in this study.

## DISCUSSION

Several authors have reported on the high rate of concurrent pathology with superior labral injuries.<sup>1,2,5,7,8,14</sup> This frequently results in concomitant procedures that make the outcomes of labral injury and repair difficult to assess. In addition, it is difficult to determine whether long-term morbidity is secondary to the labral or the additional pathology. The majority of studies evaluating the treatment of SLAP lesions have included several subtypes and combined lesions. In addition, the longest mean follow-up on any labral fixation is 35 months. The only other study to report on outcomes of type II SLAP lesions as a single entity is by Samani et al.<sup>14</sup>; however, the majority of patients in that study also underwent subacromial decompression and 1 underwent rotator cuff re-

pair. Pagnani et al.<sup>6</sup> reported good early results at minimum 1-year follow-up using a bioabsorbable tack to repair superior labral injuries; however, both type II and IV lesions were included, as well as patients who had undergone subacromial decompressions, Bankart repairs, and rotator cuff repair.<sup>6</sup> Therefore, our study is the first to address a population with isolated pathology treated with a single procedure. Our mean follow-up of 47 months provides further insight into the natural history of superior labral injuries following repair with bioabsorbable tack fixation.

Despite mean L'Insalata and ASES scores of 86, overall patient satisfaction in our series was less impressive, with good-excellent ratings in only 71%. In many cases, the inability to return to sports was a source of dissatisfaction, despite minimal pain and normal physical examinations. Only 40% of the athletes in our study were able to return to their preinjury level of performance.

Furthermore, although pain was rated as absent or mild in 83% of patients, up to 41% of patients continued to experience some degree of night pain at follow-up. We found these symptoms to be present mainly in the group whose surgical approach involved penetration of the rotator cuff. Compared with those patients in whom only a rotator interval portal was used, those in whom the cuff was penetrated had a significantly poorer outcome, both in terms of functional scores and patient satisfaction. When subgroups requiring a single tack were analyzed in an attempt to control for tear size, results still reflected poorer outcomes in the cuff-penetrated group. Furthermore, 5 of the 7 patients who had positive impingement signs at follow-up had undergone a cuff-penetrating approach. These patients did not have these symptoms preoperatively, and the 4 subacromial spaces that were examined were normal.

The outcomes of bioabsorbable tack fixation in the throwing athletes were significantly inferior to those in nonthrowing athletes. The mean ASES score in the throwing athletes was 75.9 with 38% good-excellent satisfaction compared with 84.9 and 71%, respectively in the nonthrowing group ( $P < .04$ ). These differences may be attributable to higher expectations, greater demands postoperatively, and different mechanisms of injury in the throwing athletes.

There are several other possible etiologies for the poorer outcomes. The SureTac was designed to have a bioabsorption profile that mirrors the healing response, providing dynamic fixation strength. The device loses approximately one quarter of its strength each week until 4 weeks when the device no longer

plays a mechanical role. Therefore, it is possible that the fixation may have become negligible before the healing of the labrum back to bone. This is particularly true in the posterior superior glenoid where the bone may be less dense. Furthermore, imaging studies such as magnetic resonance imaging to document persistent lesions for those with less than ideal results were not included as a part of this study.

Vangness et al.<sup>15</sup> reported on 100 cadaver shoulders in which the long head of the biceps had its major attachment posterior in 55% of cases. In 37%, the attachments were balanced between anterior and posterior. Two of our surgeons elected to approach an unstable biceps complex from a rotator interval, whereas 2 other surgeons chose to use a trans-rotator cuff approach. However, not all of the lesions were identical and some involved greater percentages of the superior-anterior labrum versus the superior-posterior labrum. Thus, another possible cause of less than ideal results was the number of surgeons and their different techniques. When analyzing the data, there was not a statistically significant difference between the 4 surgeons because of a relatively small sample size from each surgeon. However, the surgeons who performed the trans-rotator cuff approach used this technique to address the biceps anchor as well as the more posterior lesions and this may account for some of the discrepancy in outcomes scores.

### CONCLUSIONS

Overall, this study confirms that, despite acceptable outcome scores, type II SLAP injuries are difficult problems to treat successfully. This may be partly due to high expectations and demands in the athletes in whom they frequently occur. In addition, the nature of the injury itself may predispose the shoulder to future problems. By examining a group with isolated labral pathology treated with a single procedure, this study helps us better understand the outcomes of type II SLAP repairs, and therefore more accurately guide our own and our patients' expectations. Furthermore, this study confirms the importance of correctly diagnosing labral pathology as the true cause of the patient's pain. Two patients had instability that may better have been treated with other or additional procedures. Finally, this study suggests that placing por-

als through the rotator cuff may be associated with poorer surgical outcomes.

**Acknowledgment:** The authors thank Ana Castillo, Sam Taylor, Ronda Alexander, M.D., Brandon Green, Nathan Breazeale, M.D., Jeffrey Dugas, M.D., William Hobbs, M.D., and Hollis Potter, M.D., for their contributions to this study.

### REFERENCES

1. Andrews JR, Carson WG Jr, McLeod WD. Glenoid labrum tears related to the long head of the biceps. *Am J Sports Med* 1985;13:337-341.
2. Snyder SJ, Karzel RP, Del Pizzo W, Ferkel RD, Friedman MJ. SLAP lesions of the shoulder. *Arthroscopy* 1990;6:274-279.
3. Altchek DW, Warren RF, Wickiewicz TL, Ortiz G. Arthroscopic labral debridement. A three-year follow-up study. *Am J Sports Med* 1992;20:702-706.
4. Cordasco FA, Steinmann S, Flatow EL, Bigliani LU. Arthroscopic treatment of glenoid labral tears. *Am J Sports Med* 1993;21:425-431.
5. Snyder SJ, Banas MP, Karzel RP. An analysis of 140 injuries to the superior glenoid labrum. *J Shoulder Elbow Surg* 1995;4:243-248.
6. Pagnani MJ, Speer KP, Altchek DW, Warren RF, Dines DM. Arthroscopic fixation of superior labral lesions using a biodegradable implant: A preliminary report. *Arthroscopy* 1995;11:194-198.
7. Yoneda M, Hirooka A, Saito S, Yamamoto T, Ochi T, Shino K. Arthroscopic stapling for detached superior glenoid labrum. *J Bone Joint Surg Br* 1991;73:746-750.
8. Field LD, Savoie FH III. Arthroscopic suture repair of superior labral detachment lesions of the shoulder. *Am J Sports Med* 1993;21:783-790.
9. Resch H, Golser K, Thoeni H, Sperner G. Arthroscopic repair of superior glenoid labral detachment. *J Shoulder Elbow Surg* 1993;2:147-155.
10. Richards RR, An KN, Bigliani LU, et al. A standardized method for assessment of shoulder function. *J Shoulder Elbow Surg* 1994;3:347-352.
11. L'Insalata JC, Warren RF, Cohen SB, Altchek DW, Peterson MG. A self-administered questionnaire for assessment of symptoms and function of the shoulder. *J Bone Joint Surg Am* 1997;79:738-748.
12. O'Brien SJ, Pagnani MJ, Fealy S, McGlynn SR, Wilson JB. The active compression test: A new and effective test for diagnosing labral tears and acromioclavicular joint abnormality. *Am J Sports Med* 1998;26:610-613.
13. O'Brien SJ, Allen AA, Coleman SH, Drakos MC. The trans-rotator cuff approach to SLAP lesions: Technical aspects for repair and a clinical follow-up of 31 patients at a minimum of 2 years. *Arthroscopy* 2002;18:372-377.
14. Samani JE, Marston SB, Buss DD. Arthroscopic stabilization of type II SLAP lesions using an absorbable tack. *Arthroscopy* 2001;17:19-24.
15. Vangness CT, Jorgenson SS, Watson T, Johnson DL. The origin of the long head of the biceps from the scapula and glenoid labrum. An anatomical study of 100 shoulders. *J Bone Joint Surg Br* 1994;76:951-954.