

# Effective Glenoid Version in Professional Baseball Players

Mark C. Drakos, MD, Joseph U. Barker, MD, Daryl C. Osbahr, MD, Scott Lehto, MD, Jonas R. Ruzki, MD, Hollis Potter, MD, Struan H. Coleman, PhD, MD, Answorth A. Allen, MD, and David W. Altchek, MD

## Abstract

The pathomechanics of the throwing shoulder have yet to be fully elucidated. The focus of this study reported here was to further characterize the morphology of the glenoid in a population of elite throwing athletes.

We obtained magnetic resonance imaging scans of 38 professional baseball players (domi-

nant shoulders) and of 35 age-matched nonthrowing control patients (17 dominant and 18 nondominant shoulders). Seven measurements were made by 3 blinded reviewers on 3 axial images per patient: version of superior glenoid, middle glenoid, inferior glenoid, superior capsulolabral junction, middle capsulolabral junction, inferior capsulolabral junction, and depth of concavity of glenoid in a middle slice.

The kinematics of the shoulder joint in throwers represents a unique balance of mobility and stability. Over several years, baseball players place extreme, repetitive forces across the glenohumeral joint while throwing. Their successful performance is related in part to the adaptive changes made in response to repetitive overhead activities.

Dr. Drakos is Foot and Ankle Fellow, Brown University, Providence, Rhode Island.

Dr. Barker is Sports Medicine Fellow, Rush University, Chicago, Illinois.

Dr. Osbahr is Orthopedics Resident, Hospital for Special Surgery, New York, New York.

Dr. Lehto is Radiology Attending, State University of New York Downstate, New York, New York.

Dr. Rudzki is Sports Medicine Attending, Washington Orthopedics and Sports Medicine, Washington DC.

Dr. Potter is Radiology Attending, Hospital for Special Surgery, New York, New York.

Dr. Coleman is Sports Medicine Attending, Hospital for Special Surgery, New York, New York, and Associate Team Physician, New York Mets.

Dr. Allen is Sports Medicine Attending, Hospital for Special Surgery, New York, New York, and Former Associate Team Physician, New York Mets.

Dr. Altchek is Chief, Sports Medicine Service, Hospital for Special Surgery, New York, New York, and Head Team Physician, New York Mets.

Address correspondence to: Mark C. Drakos, MD, University Orthopedics, Brown University, 100 Butler Dr, Providence, RI 02906 (tel, 212-920-1619; e-mail, mdrakos@yahoo.com).

*Am J Orthop.* 2010;39(7):XX-XX. Copyright Quadrant HealthCom Inc. 2010. All rights reserved.

**“There are both osseous and soft-tissue adaptations to throwing, and these adaptations change the overall shape of the glenoid in elite throwers.”**

Mean age of the 38 players (24 pitchers, 14 fielders) was 26.8 years, and mean age of the 35 control patients was 27.6 years. Intraclass correlation coefficients ranged from .55 to .84 for the version measurements. There were no statistically significant differences between the pitchers and the fielders on any of the 7 measurements, but such differences were found between the throwers and the dominant-shoulder control patients on all 7 measurements. There were only 2 differences (version of superior glenoid, depth of concavity of glenoid in a middle slice) between dominant- and non-dominant-shoulder control patients.

There was significantly more retroversion in the osseous and soft tissues of the elite throwing athletes than in the nonthrowing control patients. This increased retroversion may play a role in development of internal impingement in the overhead athlete.

Baseball pitchers have been found to have a maximum internal rotation velocity of upwards of 7000° per second, which is the fastest motion of all overhead athletes.<sup>1,2</sup> Furthermore, velocity can be optimized by expanding the arc of rotation—that is, increasing the external rotation in the late cocking phase of throwing.<sup>3</sup>

To this end, several adaptations occur in throwing athletes. These adaptations include increased glenohumeral external rotation, increased humeral head and glenoid retroversion, and anterior capsular laxity.<sup>4-10</sup> As a result, several compensatory and potentially pathologic anatomical changes may occur within the osseous and nonosseous structures of the shoulder joint. Each of these variants has been

implicated in the pathogenesis of internal impingement.

*Internal impingement* is defined as clinical symptoms arising from abnormal contact of the rotator cuff and the posterosuperior labrum. Several causes have been theorized, including excessive anterior laxity and posterior capsular tightness.<sup>5,11</sup> In either case, the constellation of pathology encountered is extensive and includes articular-sided rotator cuff tears, superior anterior and posterior labral tears, long head of biceps tendinosis, glenohumeral internal rotation deficit, and glenohumeral instability.<sup>5,8,11-18</sup> What remains unclear is the effect of the normal adaptations on the natural history of the throwing shoulder in terms of developing or preventing internal impingement.

For the osseous adaptations, particular emphasis has been placed on the proximal humerus, as several studies have demonstrated changes within its bony architecture.<sup>4,7,19</sup> These studies have demonstrated that throwers have more retroversion in the proximal humerus, and this correlated with increased external rotation of the shoulder. As the adolescent continues to pitch, the humerus continues to change—the likely result of repetition and increased muscle mass, which leads to stronger forces occurring across the glenohumeral joint. Furthermore, 80% of the longitudinal growth of the humerus has been attributed to the proximal physis. Combined with the acceleration of growth during this period, the thrower's shoulder has both the biologic environment and the mechanical stimulus to adapt to this motion.

However, there has been little correlation with these morphologic variations and the natural history of the thrower's shoulder. The relationship between humeral retroversion and injury has not been established. Furthermore, the osseous and capsulolabral adaptations of the glenoid have been less well defined. One might suspect that

there should be a commensurate adaptation across the glenoid, as the majority of these forces are placed across the glenohumeral joint. Investigators have found an increase in osseous glenoid retroversion of the dominant shoulder in throwers.<sup>4</sup> The role of the labrum within this group, however, has yet to be defined. Moreover, the effective glenoid version could play an important role in the pathomechanics of throwers. Recently, Tetreault and colleagues<sup>17</sup> reported a statistically significant correlation between glenoid version and the anteroposterior location of rotator cuff tears in a group of nonthrowers. What is still unknown is whether this version is protective or predisposes to injury in the throwing population.

We contend that osseous and capsulolabral adaptations alter the effective glenoid version and ultimately change the shape of the glenoid in professional baseball players and may play a role in the development of the pathology commonly encountered within the spectrum of internal impingement. Since the creation of a radiographic protocol for assessing the osseous and capsulolabral glenoid version, by Kim and colleagues,<sup>20</sup> we have been able to evaluate how these measurements differ between populations, including overhead athletes.

The purpose of this study was to determine if the effective glenoid version as measured by capsulolabral and osseous angles differs between professional baseball players and the general population. In testing this hypothesis, we sought to contribute to the understanding of

the role of glenoid osseous adaptation and the development of pathologic internal impingement within professional baseball players.

## MATERIALS AND METHODS

### Patient Selection

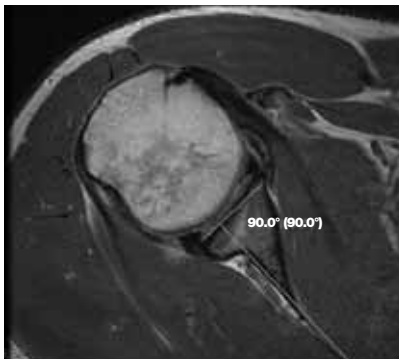
This protocol was approved by our institutional review board. We retrospectively reviewed the charts of 38 consecutive male professional baseball players from a Major League Baseball team who had undergone magnetic resonance imaging (MRI) of their throwing shoulders at our institution between January 2002 and January 2007. In all cases, the MRI was performed for evaluation of shoulder pain. We also obtained an age- and sex-matched cohort of nonthrowing control patients who had undergone MRI at our institution for the evaluation of shoulder pain. These individuals were neither professional nor recreational throwers and had shoulder pain for a variety of reasons, including rotator cuff tendinitis and shoulder bursitis. Thirty-five consecutive control patients with MRI findings negative for partial- or full-thickness rotator cuff tear, labral tear, chondral lesion, osteoarthritis, Hill-Sachs lesion, or Bankart lesion were included in this study. Patients with these pathologies were included in the throwers group.

### Magnetic Resonance Imaging

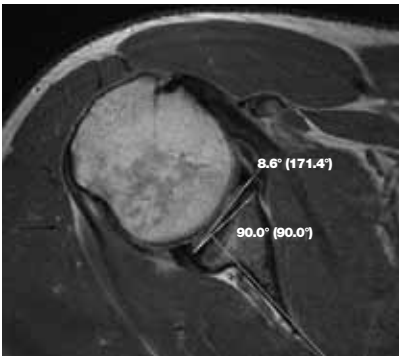
All the professional baseball players and control patients underwent MRI at our institution. All scans were performed without contrast on a 1.5-Tesla scanner (Signa Horizon

**Table 1. Comparison of Version Measurements (in Degrees) Between Professional Baseball Pitchers and Fielders**

Plane	Pitchers (n = 24)		Fielders (n = 14)		P
	M	SD	M	SD	
Superior glenoid	10.2	4.3	9.7	5.7	.76
Superior capsulolabral	10.7	4.3	9.1	6.6	.44
Middle glenoid	9.0	4.8	7.0	5.9	.18
Middle capsulolabral	10.5	5.3	9.2	6.1	.79
Middle depth	9.4	2.3	9.2	2.1	.98
Inferior glenoid	7.1	3.8	4.4	6.1	.09
Inferior capsulolabral	9.1	6.0	8.7	5.5	.56



**Figure 1.** Axial view of middle cut of glenoid. Line parallel to and line perpendicular to axis of scapular plane are drawn.



**Figure 2.** After line from most lateral margins of osseous glenoid is drawn anteriorly and posteriorly, angle is measured referencing off perpendicular line drawn in Figure 1. This angle gives retroversion of glenoid.

LX; General Electric Medical Systems, Milwaukee, Wisc) with a dedicated shoulder coil (MedRad multipurpose array, Indianola, Pa). Pulse sequence parameters included:

- Oblique coronal fast spin-echo (FSE) fat-suppressed sequence: repetition time (TR), 4000 ms; echo time (TE), 80 ms; echo train length (ETL), 8-10; matrix, 256×224; slice thickness (THK), 3 mm (no interslice gap); field of view (FOV), 16 cm; fat suppression.

- Oblique coronal proton density FSE: TR, 4000 ms; TE, 34 ms; ETL, 8-14; matrix, 512×384; THK, 3 mm (no interslice gap); FOV, 16 cm.

- Oblique sagittal proton density FSE: TR, 3500-4000 ms; TE, 34 ms; ETL, 8-12; matrix, 512×224; THK, 4 mm (skip 0.5 mm); FOV, 16 cm.

- Axial proton density FSE: TR, 4000 ms; TE, 34 ms; ETL, 8-14;

matrix, 512×384; THK, 3.5 mm (no interslice gap); FOV, 15-16 cm.

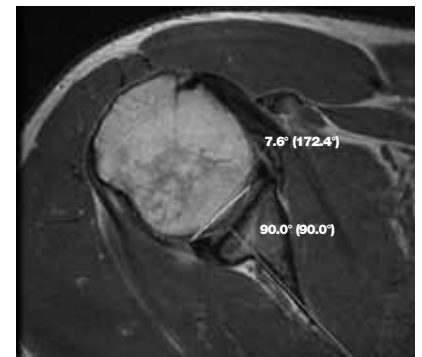
In all cases, the arm was held at the side of the trunk with the shoulder in neutral rotation. The oblique coronal proton density FSE images were used to localize the superior, middle, and inferior aspects of the glenoid. The oblique coronal images of the 25%, 50%, and 75% points along the glenoid were then used to determine the superior, middle, and inferior images used on the axial proton density FSE series. The corresponding axial images were then selected out on the FSE sequences for each of the 3 reviewers to evaluate.

### Measurements

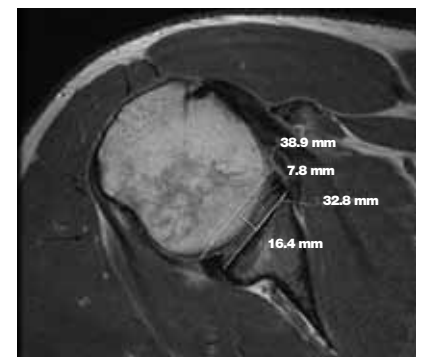
Seven measurements were used to evaluate osseous glenoid version, capsulolabral glenoid version, and glenoid depth. The method used was similar to the method previously published.<sup>20</sup> Initially, a line was drawn through the midpoint of the transverse glenoid diameter at the level of the articular surface and the medial rim of the scapular body. This established the axis of the scapula. A perpendicular line was drawn to this first line, which also passed through the most lateral aspect of the posterior glenoid (Figure 1). This second line served as our reference line for the osseous version measurements. The angle between the anterior and posterior aspects of the glenoid and the reference line defined the osseous version of the glenoid (Figure 2). A similar process was performed for the labrum at the most lateral aspect of the capsulolabral junction (Figure 3). For the labral measurements, a perpendicular line was drawn to the axis of the scapula, which also passed through the most lateral aspect of the posterior glenoid labrum. Glenoid depth was defined as the distance from the midpoint of the glenoid articular surface to a line drawn through the tips of the anterior and posterior aspects of the labrum (Figure 4). For each location on the glenoid (superior,

middle, inferior), both osseous glenoid version and capsulolabral glenoid version were measured. For the middle axial image (at the 50% mark on the glenoid), glenoid depth was measured.

Positive angles represented retroversion, and negative angles represented anteversion. Three blinded observers (2 orthopedic surgeons, 1 radiologist) performed each of the measurements. All measurements were performed on the Picture Archiving and Communications System (PACS) monitor using standard angle- and length-calculating software. We performed reliability analysis, repeated-measures analysis of vari-



**Figure 3.** After line from most lateral margins of capsulolabral junction is drawn anteriorly and posteriorly, angle is measured referencing off perpendicular line drawn in Figure 1. This angle gives effective retroversion of labrum.



**Figure 4.** Measurement of glenoid depth. Distance measured from most lateral margins of osseous glenoid anteriorly and posteriorly (32.8 mm) is halved to pick a point in middle of glenoid (16.4 mm). Then, line from most lateral margins of capsulolabral junction is drawn anteriorly and posteriorly (38.9 mm). Shortest distance from middle portion of glenoid to this capsulolabral line is recorded (7.8 mm).

ance, and post hoc analysis. *P* was set at .05 for statistical significance.

## RESULTS

We reviewed the MRIs of the dominant shoulders of 38 professional baseball players (24 pitchers, 14 fielders; mean age, 26.8 years). We also reviewed the MRIs of 35 nonthrowers (17 dominant and 18 nondominant shoulders; mean age, 27.6 years). Of the 38 players, 25 had a clinical diagnosis of internal impingement, and 1 had a prior acromioplasty for subacromial impingement. Players' MRI findings included ganglion cyst (*n* = 20), superior labral anterior to posterior (SLAP) tear (15), partial supraspinatus tendon tear (11), partial infraspinatus tear (9), Bennett lesion (9), Hill-Sachs lesion (6), acromioclavicular joint arthrosis (2), Bankart lesion (1), os acromiale (1), and inferior glenohumeral ligament complex tear (1). For the control patients, there was no evidence of these pathologies on MRI. Ultimately, the majority of the control patients received a diagnosis of shoulder strain.

Regarding interobserver reliability, correlation coefficients were .73 (superior glenoid), .84 (superior capsulolabral junction), .62 (middle glenoid), .75 (middle capsulolabral junction), .30 (middle depth), .55 (inferior glenoid), and .68 (inferior capsulolabral junction). With the exception of glenoid depth, all these measurements demonstrated good interobserver reliability.

For all 7 measurements, there was no statistically significant dif-

ference between the pitchers and fielders in the players group (Table I), so we combined those subgroups into a "throwers" group for comparison with both the dominant and the nondominant-shoulder control groups.

Table II summarizes the measurements for each of the 3 groups (throwers, dominant-shoulder control patients, nondominant-shoulder control patients). With respect to glenoid version, there was a statistically significant difference between the throwers and the dominant- and nondominant-shoulder control patients for superior, middle, and inferior glenoid version.

With respect to the glenoid, mean increase in retroversion between the throwers and the dominant-shoulder control patients was 3.9°, 6.9°, and 3.1° for the superior, middle, and inferior measurements, respectively. Each increase was statistically significant. With respect to the capsulolabral junction, the magnitude of the difference was 4.0°, 6.1°, and 5.0°. These increases were also significant.

On average, the labrum added 1.8° of retroversion on the middle slice and 2.7° of retroversion on the inferior slice for the throwers. The depth of the glenoid was larger for the throwers (8.8 mm) than for the dominant-shoulder control patients (7.5 mm) or the nondominant-shoulder control patients (6.4 mm).

Differences between the throwers and the nondominant-shoulder control patients were 7.1°, 6.2°, and 2.8° for the glenoid and 6.2°, 5.8°, and 5.4° for the capsulolabral junction.

These were all statistically significant.

Differences between the dominant- and the nondominant-shoulder control patients were 3.2°, -0.7°, and -0.3° for the glenoid and 2.2°, -0.3°, and 0.4° for the capsulolabral junction. The superior glenoid provided the only statistically significant version difference—more retroversion in the dominant-shoulder control patients.

## DISCUSSION

Our study results demonstrated both osseous and soft-tissue adaptations in the throwing shoulder. This finding is consistent with that of studies that have used computed tomography (CT) and radiographs to evaluate glenoid version.<sup>4</sup> Our mean retroversion was slightly less than that reported by Crockett and colleagues.<sup>4</sup> MRI and use of PACS measurement tools allowed accurate and reproducible measurement of glenoid version. Unlike CT, they also allowed for accurate representation of soft-tissue structures, which is important because characterization of the effective glenoid version includes the labrum, which deepens the glenoid socket. The labrum added 1° to 2° of retroversion in professional baseball players at the middle and inferior aspect of the glenoid—demonstrating a soft-tissue adaptation to repetitive throwing, in addition to the osseous adaptation. Furthermore, there was a deepening of the osseous glenoid in throwers versus control patients. The discrepancy within a single individual of glenoid and capsulolabral retroversion combined with the

**Table II. Comparison of Version Measurements (in Degrees) Between Professional Baseball Players and Dominant (DC) and Nondominant (NDC) Shoulders of Control Patients**

Plane	Throwers ( <i>n</i> = 38)		Control Patients ( <i>n</i> = 35)				<i>P</i>	
	Mean	SD	DC ( <i>n</i> = 17)		NDC ( <i>n</i> = 18)		Throwers vs DC Controls	Controls: DC vs NDC
			Mean	SD	Mean	SD		
Superior glenoid	10.0	4.8	6.1	4.4	2.9	4.6	.002	.02
Superior capsulolabral	10.0	5.1	6.0	5.3	3.8	4.5	.004	.18
Middle glenoid	8.3	5.2	1.4	5.7	2.1	5.2	<.001	.64
Middle capsulolabral	10.1	5.6	4.0	5.5	4.3	5.7	<.001	.86
Middle depth	9.3	2.2	7.9	1.7	6.9	1.4	<.001	.01
Inferior glenoid	6.3	4.6	3.2	4.4	3.5	4.7	.012	.82
Inferior capsulolabral	9.0	5.8	4.0	6.1	3.6	6.5	.002	.83



deepening of the glenoid suggests that these adaptations represent changes in the 3-dimensional shape of the socket rather than simple 2-dimensional changes in version.

As there was no difference between pitchers and fielders in our cohort, these changes may depend on a threshold number of throws or on years of throwing, rather than on throwing at extremely high velocities or intensity, as would be seen in the pitching cohort. Furthermore, these changes likely take place during the developmental phases of growth in the pubescent years.<sup>3,9</sup> It is also plausible that these throwers have self-selected. Their glenohumeral joints have adapted to allow them to throw at high levels by permitting increased external rotation in abduction by humeral and glenoid retroversion. In essence, this increased retroversion may be biomechanically necessary for throwing a baseball at high velocity. What remains unclear is the effect that increased retroversion has on the natural history of the throwing shoulder and the development of pathology.

*Internal impingement*, well described in the orthopedic literature, refers to the pathologic contact between the margin of the glenoid and the articular surface of the rotator cuff and classically presents in overhead athletes. Increased soft-tissue and osseous retroversion may play a role in development of internal impingement in the overhead athlete. All the baseball players in our study underwent MRI and had pain in the dominant shoulder from repetitive activity, and many had been clinically diagnosed with internal impingement. MRI revealed a variety of pathologies, including SLAP tears, articular-sided rotator cuff tears, and Bennett lesions. In a study of handball players, Pieper<sup>21</sup> found less humeral retroversion (mean, 5.4°) in those with chronic arm pain than in those without pain and suggested that humeral retroversion may in fact be protective in the overhead athlete.

The changes on the glenoid are less likely to be protective. Although

one might propose that a simple change in retroversion may prevent internal impingement, we conclude from our study results that the changes are more morphologically complex and include deepening of the glenoid, which ultimately changes the glenoid shape. As the glenoid remodels and the posterior capsule becomes shorter, the posterior glenoid becomes more prominent. This is further emphasized by the presence of a Bennett lesion, a posterior extra-articular ossification associated with a scarred capsule. As this portion of the glenoid becomes more prominent, it increases the likelihood of undersurface contact of the rotator cuff with the posterior glenoid margin—which may lead to fraying of the rotator cuff and articular-sided rotator cuff tears.

## CONCLUSIONS

There are both osseous and soft-tissue adaptations to throwing, and these adaptations change the overall shape of the glenoid in elite throwers. Changing the mechanics of motion defined by osseous and soft-tissue restraints may prolong a thrower's career before overuse injury occurs. Furthermore, this increased retroversion may be biomechanically necessary for throwing a baseball at high velocity.

Although it is still unclear whether it is protective or deleterious, effective glenoid retroversion may one day become a target of therapy. More studies are needed to evaluate the effect of both humeral and glenoid retroversion on the incidence of pathology and on the biomechanics of the thrower's shoulder.

## AUTHORS' DISCLOSURE STATEMENT

The authors report no actual or potential conflict of interest in relation to this article.

## REFERENCES

1. Fleisig GS, Andrews JR, Dillman CJ, Escamilla RF. Kinetics of baseball pitching with implications about injury mechanisms. *Am J Sports Med.* 1995;23(2):233-239.
2. Fleisig GS, Dillman CJ, Andrews JR. Biomechanics of the shoulder during throwing.

- In: Andrews JR, Wilk KE, eds. *The Athlete's Shoulder*. New York, NY: Churchill Livingstone; 1994:360-365.
3. Matsuo T, Escamilla RF, Fleisig GS, Barrentine SW, Andrews JR. Comparison of kinematic and temporal parameters between different pitch velocity groups. *J Appl Biomech.* 2001;17(1):1-13.
4. Crockett HC, Gross LB, Wilk KE, et al. Osseous adaptation and range of motion at the glenohumeral joint in professional baseball pitchers. *Am J Sports Med.* 2002;30(1):20-26.
5. Jobe FW, Giangarra CE, Kvitne RS, Glousman RE. Anterior capsulolabral reconstruction of the shoulder in athletes in overhead sports. *Am J Sports Med.* 1991;19(5):428-434.
6. Myers JB, Laudner KG, Pasquale MR, Bradley JP, Lephart SM. Glenohumeral range of motion deficits and posterior shoulder tightness in throwers with pathologic internal impingement. *Am J Sports Med.* 2006;34(3):385-391.
7. Osbahr DC, Cannon DL, Speer KP. Retroversion of the humerus in the throwing shoulder of college baseball pitchers. *Am J Sports Med.* 2002;30(3):347-353.
8. Paley KJ, Jobe FW, Pink MM, Kvitne RS, ElAttrache NS. Arthroscopic findings in the overhead throwing athlete: evidence for posterior internal impingement of the rotator cuff. *Arthroscopy.* 2000;16(1):35-40.
9. Sabick MB, Kim YK, Torry MR, Keirns MA, Hawkins RJ. Biomechanics of the shoulder in youth baseball pitchers: implications for the development of proximal humeral epiphysiolysis and humeral retrotorsion. *Am J Sports Med.* 2005;33(11):1716-1722.
10. Werner SL, Gill TJ, Murray TA, Cook TD, Hawkins RJ. Relationships between throwing mechanics and shoulder distraction in professional baseball pitchers. *Am J Sports Med.* 2001;29(3):354-358.
11. Burkhart SS. Internal impingement of the shoulder. *Instr Course Lect.* 2006;55:29-34.
12. Edelson G, Teitz C. Internal impingement in the shoulder. *J Shoulder Elbow Surg.* 2000;9(4):308-315.
13. Halbrecht JL, Tirman P, Atkin D. Internal impingement of the shoulder: comparison of findings between the throwing and nonthrowing shoulders of college baseball players. *Arthroscopy.* 1999;15(3):253-258.
14. Jobe CM, Coen MJ, Scenera P. Evaluation of impingement syndromes in the overhead-throwing athlete. *J Athl Train.* 2000;35(3):293-299.
15. Meister K. Internal impingement in the shoulder of the overhead athlete: pathophysiology, diagnosis, and treatment. *Am J Orthop.* 2000;29(6):433-438.
16. Meister K, Buckley B, Batts J. The posterior impingement sign: diagnosis of rotator cuff and posterior labral tears secondary to internal impingement in overhead athletes. *Am J Orthop.* 2004;33(8):412-415.
17. Tetreault P, Krueger A, Zurakowski D, Gerber C. Glenoid version and rotator cuff tears. *J Orthop Res.* 2004;22(1):202-207.
18. Tischer T, Salzmann GM, Imhoff AB. Rotator cuff tears and internal impingement in athletes. *Orthopade.* 2007;36(10):950-956.
19. Reagan KM, Meister K, Horodyski MB, Werner DW, Carruthers C, Wilk K. Humeral retroversion and its relationship to glenohumeral rotation in the shoulder of college baseball players. *Am J Sports Med.* 2002;30(3):354-360.
20. Kim SH, Noh KC, Park JS, Ryu BD, Oh I. Loss of chondrolabral containment of the glenohumeral joint in atraumatic posteroinferior multidirectional instability. *J Bone Joint Surg Am.* 2005;87(1):92-98.
21. Pieper HG. Humeral torsion in the throwing arm of handball players. *Am J Sports Med.* 1998;26(2):247-253.