

Arthroscopic Subdeltoid Approach to the Biceps Transfer

Stephen J. O'Brien, MD, Anna N. Miller, MD, and Mark C. Drakos, MD

Arthroscopy is an accepted tool in the treatment of many types of shoulder pathology. The arthroscopic subdeltoid approach consists of the posterior-portal-based arthroscope being advanced into the subdeltoid space via the subacromial space, then exposure of the space with shaving or radiofrequency ablation. The other portals are then made with a spinal needle localization piercing the anterior deltoid. This subdeltoid approach is well-suited to problems such as pectoralis major and subscapularis muscle tear, as well as massive rotator cuff tear repairs, problems that were previously difficult to address from the standard arthroscopic portals. This approach also allows transfer of the biceps tendon to the conjoint tendon. When patients continue to be symptomatic despite conservative interventions, surgical options need to be explored. Currently, there is no gold standard for the surgical treatment of biceps tendon pathology. Some authors favor tenodesis whereas others advocate tenotomy or transfer. Many of the treatments, including tenodesis and tenotomy, have had excellent rates of success, but complications, such as deformity, persist. We describe a new arthroscopic technique for biceps tenodesis via transfer of the long head of the biceps tendon to the conjoint tendon using the subdeltoid space. With this technique, the tendons are under direct visualization for proper tensioning, and the transferred tendon is approximately in the same orientation as in its native location. In the appropriately indicated patient, this technique may yield relief from biceps specific symptoms.

Oper Tech Sports Med 15:20-26 © 2007 Elsevier Inc. All rights reserved.

KEYWORDS subdeltoid arthroscopy, biceps transfer, biceps tendonitis

Arthroscopy has advanced many areas of shoulder surgery, making less-invasive surgeries both more common and equally efficacious.^{1,2} The surgical management of biceps tendon lesions is one area of shoulder arthroscopy that is still controversial. Moreover, the role of the biceps tendon as a shoulder stabilizer is still under debate.³⁻¹⁵ It is widely acknowledged that irritation of the biceps tendon can cause significant shoulder pain, possibly owing to the network of sensory sympathetic fibers that surrounds it.¹⁶

When biceps tendonitis or subluxation continues despite nonoperative management, several procedures have been used to relieve these symptoms. The 3 main surgical options for treatment of biceps tendonopathy are tenodesis, tenotomy, and tendon transfer. In the first case, fixation techniques such as bone tunnels, anchors, staples, and interference screws all have been used to fix the tendon to the

proximal humerus.^{4,5,17-27} These have been performed both with open and arthroscopic techniques, but the use of tenodesis has been limited by complaints of pain in as many as 40% of patients postoperatively at the site of fixation.¹⁹

Tenotomy was first attempted after reports of spontaneous resolution of pain in symptomatic patients with incidental rupture of the long head of the biceps tendon.²⁸⁻³⁰ The use of tenotomy has reliably improved pain symptoms but again is complicated by complaints regarding cosmesis as well as muscle spasm. Younger patients in particular seem prone to a Popeye's sign and discomfort with overuse of the arm.^{5,19,23,31} Patients older than 60 years of age have not been shown to have a significant incidence of Popeye's sign, fatigue discomfort symptoms, or difference in strength compared with those who do not undergo with this procedure.²³

Biceps tendon transfer was first described in 1982 by Post; the long head was transferred from its supraglenoid tubercle origin to the conjoint tendon arising from the coracoid process in 4 cases with good results.³² This method was described as an arthroscopic procedure by the senior author (S.J.O.) in 2005.¹⁴ We have found an arthroscopic approach

Department of Sports Medicine, The Hospital for Special Surgery, New York, NY.

Address reprint requests to Mark C. Drakos, MD, The Hospital for Special Surgery, 535 East 70th Street, New York, NY 10021. E-mail: drakosm@hss.edu

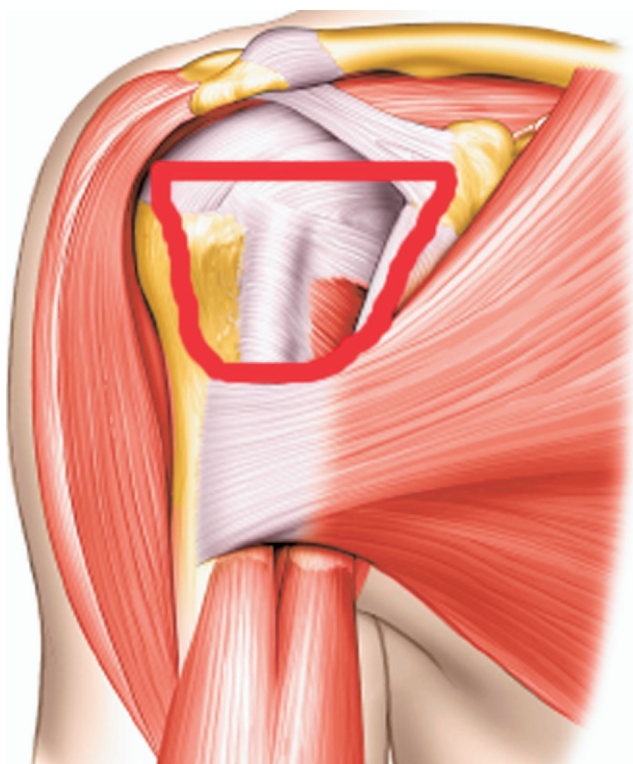


Figure 1 Graphic depiction of the subdeltoid space bordered by the conjoint tendon medially, the lateral aspect of the proximal humerus laterally, the subacromial bursa superiorly and the pectoralis major tendon inferiorly. (Please note all figures are of a right shoulder.)

to this tendon transfer to be a successful procedure that reliably produces good results in our patients. The arthroscopic approach is via the subdeltoid space, allowing excellent access to the anterior, extra-articular aspect of the shoulder.

Indications

Patients who present with biceps tendon pathology are first treated nonoperatively with a multidisciplinary approach.

Activity modification, physical therapy (including periscapular muscle strengthening), injections of local anesthetics as well as steroids (with or without ultrasound guidance), and oral anti-inflammatory medications are all options that should be considered before surgical intervention. It appears that many of these patients may be more difficult to treat than those with other types of impingement, such as standard subacromial impingement.²⁵ Biceps instability may be an etiology contributing to symptoms and may be associated with subscapularis tears. Intra-articular instability can be the result of overall shoulder laxity, a SLAP tear, or an unstable biceps anchor, whereas extra-articular subluxation can be the result of a tear or laxity of the transverse humeral ligament or subscapularis tendon. Pathology in the bicipital groove itself also can lead to pain.³³

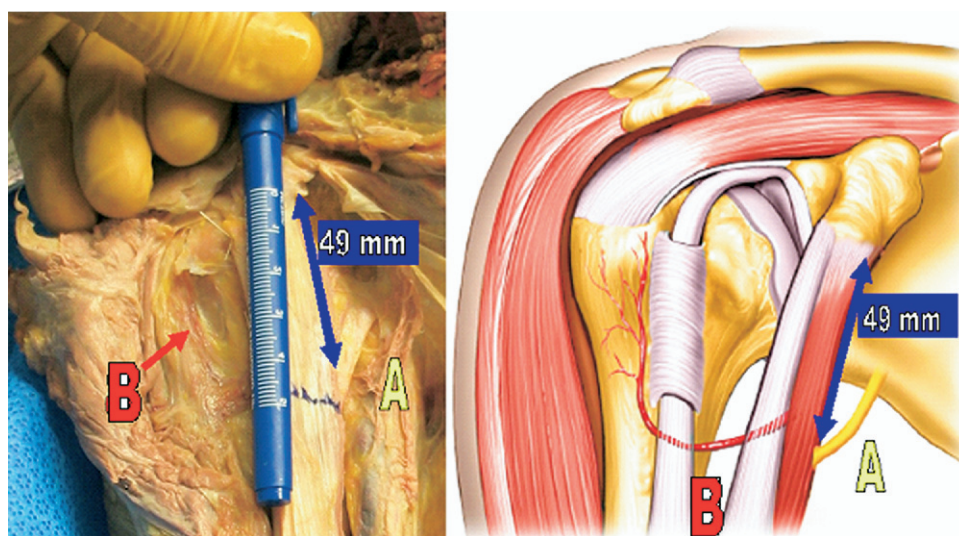
Physical examination of the shoulder may have a variety of positive findings, including pain with palpation of the bicipital groove or a positive active compression test.³⁴ Speed and Yerguson Tests also may be positive in these patients. The senior author also performs a “throwing test” in which the patient performs a pitcher’s throwing motion as resistance is applied to that shoulder. Extra-articular biceps subluxation will cause pain in the anterior shoulder resulting in a positive test.

Surgery is indicated for those patients refractory to nonoperative management. If patients younger than 60 years of age have a viable biceps tendon with no other pathology or pathology limited to the biceps and rotator cuff, the senior author (S.J.O.) routinely performs a tendon transfer of the long head of the biceps with an arthroscopic subdeltoid approach.

Anatomy of the Subdeltoid Space

The boundaries of the subdeltoid space include the greater tuberosity superiorly, the long head of the biceps tendon laterally, the pectoralis major tendon inferiorly, and the conjoint tendon medially (Fig. 1). The anterior deltoid forms the

Figure 2 Neurovascular structures at risk in the subdeltoid space. (A) Musculocutaneous nerve, which enters the conjoint tendon approximately 49 mm from the tip of the coracoid; (B) ascending branch of the anterior humeral circumflex.



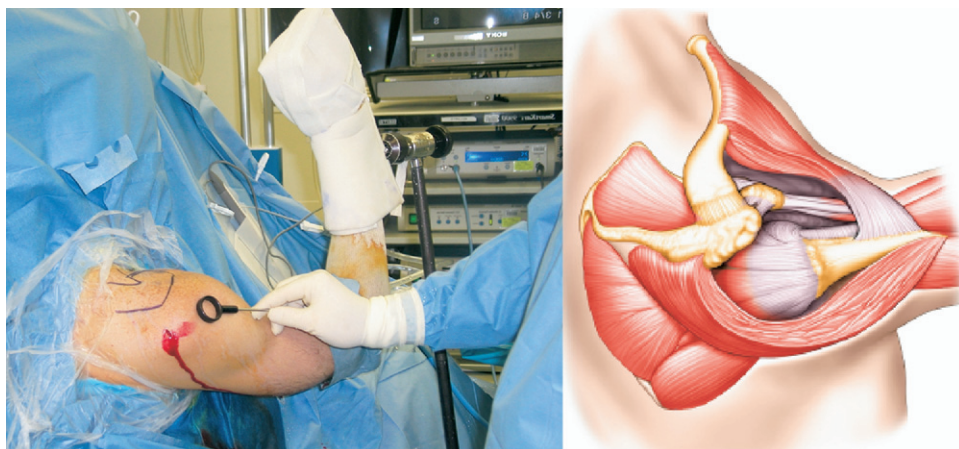


Figure 3 The 90 to 90-15 position for subdeltoid arthroscopy is shown. The humeral head has fallen posteriorly due to gravity to allow the space to open.

roof and the anterior shoulder capsule forms the floor of this space. While working in this space, there are 2 neurovascular structures that are at particular risk. The musculocutaneous nerve courses inferiorly and laterally to innervate the short head of the biceps and coracobrachialis. In a cadaveric study, Bach and colleagues³⁵ found that the nerve enters the conjoint tendon on an average of 49 mm below the tip of the coracoid process. However, in 5% of cases the entry site was within 25 mm of the coracoid process. Although we have only visualized this structure in approximately 5% of our cases, it is important to be cognizant of the proximity of the nerve to avoid complications. Second, the ascending branch of the anterior humeral circumflex artery also often is visualized running from distal to proximal within the lateral aspect of the bicipital groove. If violated, this branch will bleed significantly and should be adequately cauterized to avoid unnecessary hematoma (Fig. 2).

Technique

In the operating room, the patient is placed in a modified beach chair position. The patient is then examined under anesthesia to assess for instability and range of motion. A diagnostic arthroscopy through a standard anterior and posterior portal is performed. The anterior portal may then be used as an accessory portal for inflow later in the case. The long head of the biceps tendon (LHBT), as well as its anchor to the superior labrum, are inspected along the entire intra-articular portion. Fraying at the “creased” portion of the tendon may be a sign of instability in this area. In addition, the arthroscopic active compression test is performed.³⁶ In this test arm is forward flexed and adducted. In cases in which intra-articular instability is present, the LHBT will sublux posteriorly within the joint when this maneuver is performed. If this correlates with the patient’s clinical symptoms, an arthroscopic transfer procedure is indicated.

After confirmation of its integrity, the LHBT is released, and the remaining tissue is debrided back using a mechanical shaver. Other pathology is then addressed, including labral lesions, subacromial impingement, and rotator cuff tears as indicated by physical examination and arthroscopic findings. To enter the subdeltoid space arthroscopically, the humeral

head must be posterior in the joint to widen the subdeltoid space; to achieve this, the arm is positioned in 70° to 90° of forward flexion, 90° of elbow flexion, and 15° to 30° of sagittal abduction using a McConnell arm holder (Fig. 3). In this position, the standard posterior portal can be used for the arthroscope, and the working portal is an anterolateral portal placed at the anterior third of the acromion (Fig. 4).

The surgeon develops the subdeltoid space in a counter-clockwise direction (when viewing a left shoulder). The fas-

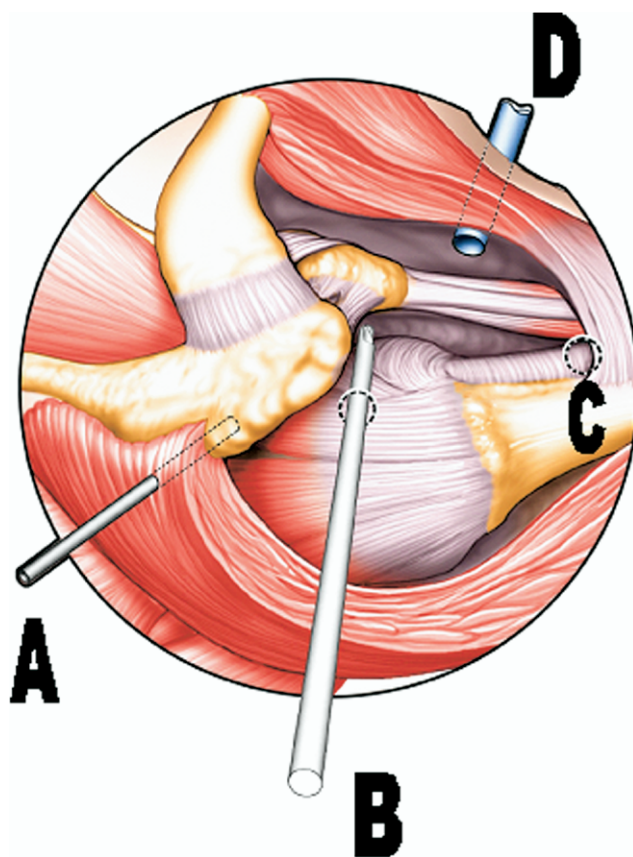


Figure 4 Portal placement for developing the subdeltoid space. (A) Posterior portal for viewing; (B) anterolateral portal used for tunneling medially; (C) site for the Pectoralis portal; (D) conjoint portal used for suture tying during transfer.

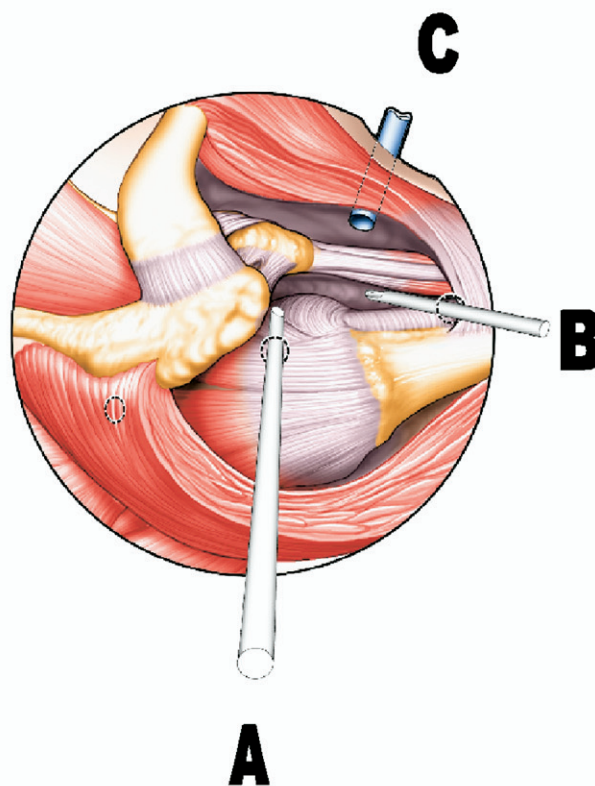
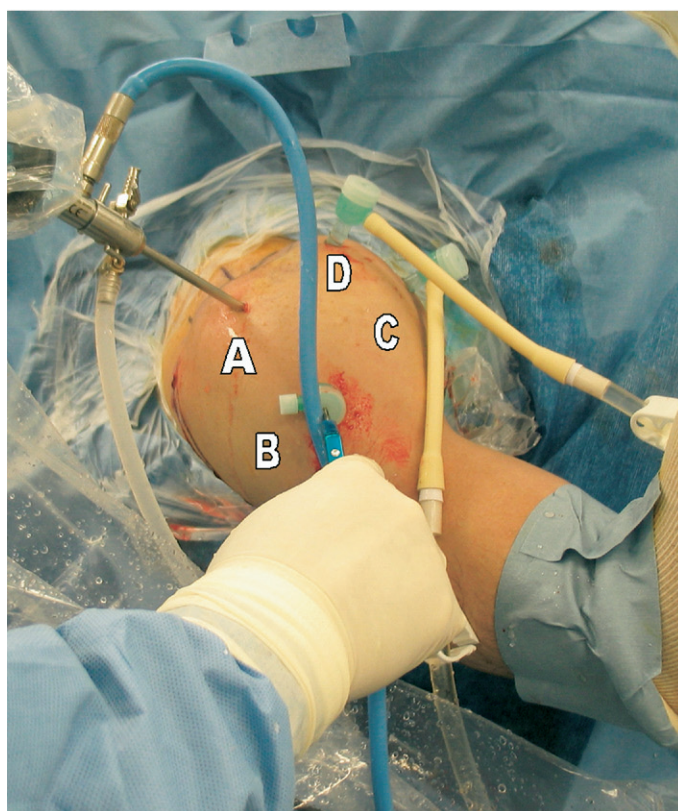


Figure 5 Subdeltoid arthroscopy portal placement. (A) Anterolateral portal used for viewing while working in the subdeltoid space; (B) pectoralis portal used for working; (C) conjoint portal used for suture tying during transfer; (D) anterior, accessory portal used for inflow. Note in the set-up on the left there are 2 inflows to allow greater insufflation of the space. On the right, there is only one inflow through the coracoid portal.

cia and subdeltoid bursa are released with an arthroscopic shaver and radiofrequency device as follows. The medial anatomic landmarks are first identified by “tunneling” through to the conjoint tendon and coracoid process medially and inferiorly. A “coracoid” portal is then made 2 cm distal to the tip of the coracoid process and in line with the conjoint tendon. Localization of all portals is accomplished with a spinal needle and cannulas are inserted under direct visualization with the arthroscope.

The surgeon then sweeps laterally with the shaver or electrofrequency device through the subdeltoid plane to identify the pectoralis major tendon inferiorly, inserting lateral to the long head of the biceps tendon and bicipital groove. The pectoralis major tendon is the inferior border of the dissection. A “pectoralis” portal is then created (as discussed previously), entering from the anterolateral deltoid at the level of the superior margin of the pectoralis major tendon. This portal is superiorly directed, allowing release of the bicipital hood as necessary. The “pectoralis” portal then becomes the working portal and the arthroscope is switched to the anterolateral portal. The arthroscope remains in the anterolateral portal and is used to visualize the bicipital sleeve while the electrofrequency probe is placed in the “pectoralis” portal at this time (Fig. 5). Usually, only a small aperture at the level of the overlying pectoralis major tendon is required to deliver the LHBT. The LHBT is delivered through this opening into

the subdeltoid space (Fig. 6). The tendon is then brought out through the skin incision of the “pectoralis” portal and tagged with 2 Ethibond Thompson traction sutures (Ethicon, Inc, Somerville, NJ). A small skin incision is then made just anterior to the superior aspect of the coracoid. This incision is used to hold the traction sutures for transfer after the tendon is reinserted into the subdeltoid space.

Inflow is placed in the coracoid and anterior accessory portals to allow insufflation of the working area. The remaining bursal attachments are then divided to provide a large working space for the surgeon. If more inflow is necessary, an accessory mid-antrolateral portal can be made halfway between the superior, anterolateral portal and the “pectoralis” portal. This portal is just lateral to the bicipital groove.

At this time, the elbow is flexed to 90° and the long head of the biceps tendon is tensioned in line with the conjoint tendon by pulling on the traction sutures until the tendon is moderately bowstrung (Fig. 7). Although this reduction is held in place by an assistant, a looped suture retriever is passed through one of the lateral portals to reduce the long head of the biceps tendon to the conjoint tendon. Another suture-passing device or spectrum is then used to pass a loop-ended No. 0 PDS suture through the biceps and conjoint tendons (Fig. 8). The loop is passed through one of the lateral portals and No. 2 Tevdek suture (Denkatek DSP, Fall River, MA) is carried back through the “conjoint” portal can-

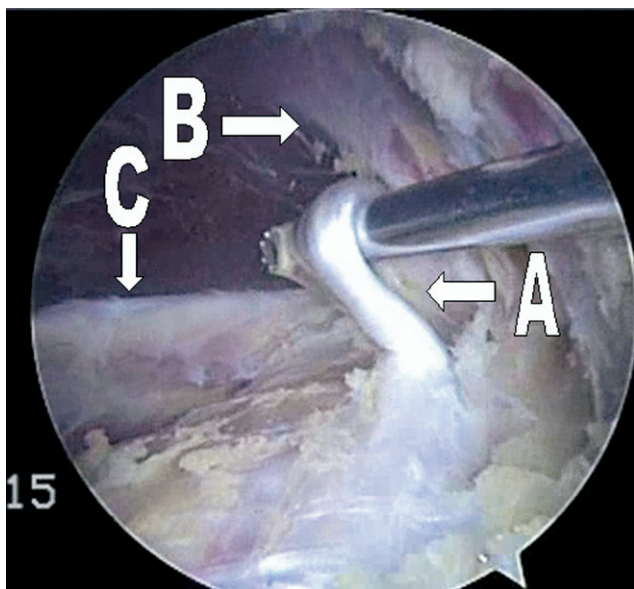


Figure 6 Viewing from the anterolateral portal an aperture is made in the bicipital sheath to allow delivery of the LHBT into the subdeltoid space. (A) LHBT; (B) pectoralis major tendon; (C) conjoint tendon. (Color version of figure is available online.)

nula. The opposite end of the No. 2 Tevdek is then retrieved out through the conjoint portal cannula and the long head of the biceps tendon is sutured into place with arthroscopic knot-tying techniques.

It is critical to suture the long head of the biceps tendon to the anterior surface of the lateral aspect of the conjoint tendon to avoid coracoid impingement or injury to the musculocutaneous nerve. Approximately 3 to 4 sutures are placed

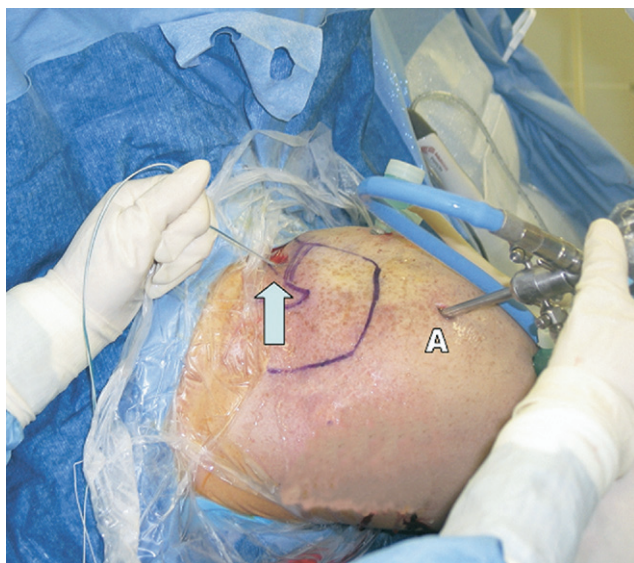

Figure 7 Tensioning of the transfer. (A) A superior aperture (arrow) is made to allow for tensioning of the transfer. This aperture is actually anterior to the coracoid and clavicle. The arthroscope (A) is located in the anterolateral portal viewing medially for this portion of the procedure. Note that shoulder edema has distorted the pre-operative landmarks. (Color version of figure is available online.)

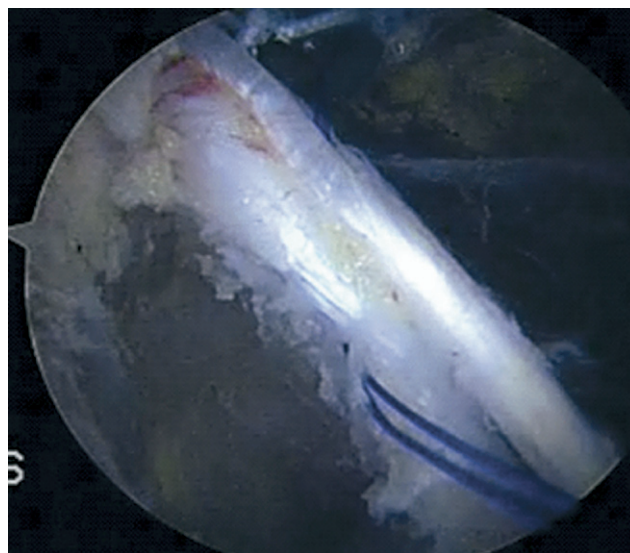


Figure 8 The long head of the biceps is sutured to the lateral aspect of the anterior surface of the conjoint tendon to avoid coracoid impingement. (Color version of figure is available online.)

in this manner to secure the transferred tendon. After the tendon is secure, the excess portion of the tendon is removed along with the tagging sutures through the superior incision. The arthroscope is left in place while the elbow is put through a full range of motion to confirm the repair. This isometric repair will appear to have little or no tension with elbow motion (Figs. 9 and 10).

Postoperative Management

Patients are placed in a sling full time for the first 3 days after surgery. The patients are then instructed to wear the sling at night and when they are going to be in crowded situations for the next 2 weeks. During this time, they are encouraged to perform active and active-assisted shoulder and elbow range

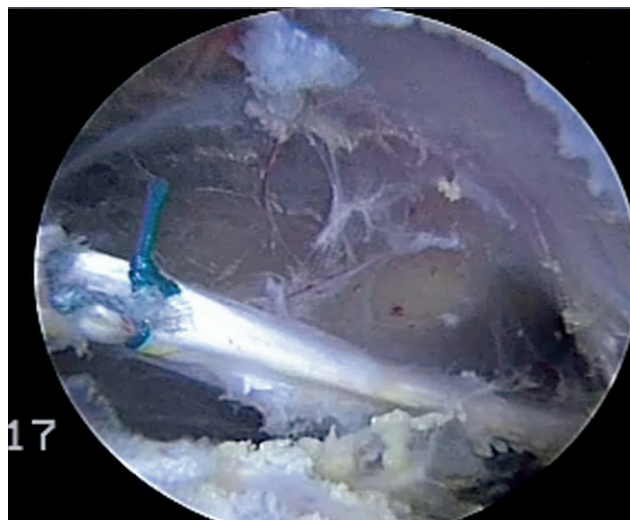


Figure 9 Completed biceps transfer. (Color version of figure is available online.)

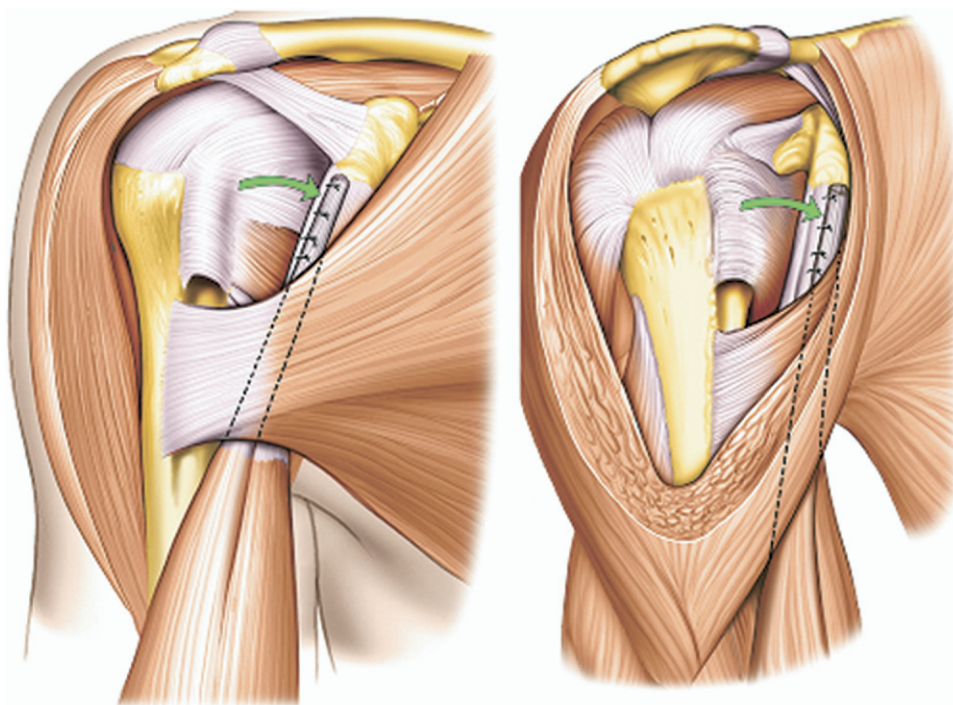


Figure 10 Graphic depiction of a completed biceps transfer.

of motion out of the sling. It is critical that the patient not to lift any objects heavier than a piece of silverware or a pen. After the first 2 postoperative weeks, formal physical therapy commences, aiming toward complete ability to perform activities of daily living at four weeks, full throwing and swimming if tolerated by three months, and unrestricted activities by 4 to 5 months.

Discussion

The senior author (S.J.O.) has performed more than 170 of these tendon transfer procedures. An operative time less than 1 hour can be obtained after a learning curve of approximately 30 procedures. Recently, Cohen and colleagues³⁷ reported good-to-excellent results in 80% to 92% (with or without other pathologies) of the patients with at least 2 years of follow-up.³⁶ These patients were also found to have statistically equal muscle strength when the operated and contralateral sides were compared, and 95% had no pain in the bicipital groove postoperatively. Of these patients, 12.5% had fatigue discomfort symptoms, and 5% had a Popeye's sign. In 2 cases, failure of the transfer was the result of noncompliance with postoperative protocols within the first 6 weeks of surgery.³⁷

The potential complications with this technique include injury to the LHBT, pectoralis major tendon, coracoid impingement, and musculocutaneous nerve injury. The pectoralis major tendon is in danger during the release of the LHBT from the bicipital groove via the incision in the tendon sheath. This sheath extends to the pectoralis major and care should be taken to properly visualize the pectoralis major tendon to avoid damage. Coracoid impingement can become a problem if the tendon is secured laterally or posteriorly along the conjoint tendon, so it is important for the surgeon to properly place the tendon on the anterior aspect of the

lateral half of the conjoint tendon. Finally, the musculocutaneous nerve enters the coracobrachialis muscle approximately 49 mm distal to the coracoid process (or within 25 mm in 5% of patients).³⁵ This anatomic landmark should be constantly kept in mind during any dissection or tension in this area.

There is a theoretical risk of compartment syndrome of the arm because there is no true capsule to contain fluid, but rather a fascial plane. We have not seen any cases of compartment syndrome with this procedure. Furthermore, we have not found any significant increase in shoulder swelling in this procedure as compared with other arthroscopic shoulder procedures as long as the surgical time is kept under two hours.

In our experience, this arthroscopic tendon transfer provides improved results over traditional procedures for many reasons. The transfer of the biceps tendon to the conjoint tendon closely reproduces the native pull of the biceps muscle and appears to be isometric. In addition, the tendon to tendon transfer gives the opportunity for soft tissue to soft-tissue healing, compared with tendon to bone healing, with no pain at the healing site, as seen with tenodesis. This recreates the normal "bungee" effect of the biceps and superior labrum complex. In addition, this technique allows the surgeon to directly visualize the tendons to properly tension them. When performed properly, this method allows surgeons to directly address biceps pathology without the morbidity of alternative procedures such as tenotomy and tenodesis.

Acknowledgments

All illustrations are courtesy of Hugh Thomas. The authors would like to thank Ana Castillo for her contributions to this manuscript.

References

1. Cole BJ, Millett PJ, Romeo AA, et al: Arthroscopic treatment of anterior glenohumeral instability: Indications and techniques. *Instr Course Lect* 53:545-558, 2004
2. Cole BJ, Warner JJ: Arthroscopic versus open Bankart repair for traumatic anterior shoulder instability. *Clin Sports Med* 19:19-48, 2000
3. Andrews JR, Carson WG Jr, McLeod WD: Glenoid labrum tears related to the long head of the biceps. *Am J Sports Med* 13:337-341, 1985
4. Curtis AS, Snyder SJ: Evaluation and treatment of biceps tendon pathology. *Orthop Clin North Am* 24:33-43, 1993
5. Eakin CL, Faber KJ, Hawkins RJ, et al: Biceps tendon disorders in athletes. *J Am Acad Orthop Surg* 7:300-310, 1999
6. Glousman R, Jobe F, Tibone J, et al: Dynamic electromyographic analysis of the throwing shoulder with glenohumeral instability. *J Bone Joint Surg Am* 70:220-226, 1988
7. Gowan ID, Jobe FW, Tibone JE, et al: A comparative electromyographic analysis of the shoulder during pitching. Professional versus amateur pitchers. *Am J Sports Med* 15:586-590, 1987
8. Itoi E, Kuechle DK, Newman SR, et al: Stabilising function of the biceps in stable and unstable shoulders. *J Bone Joint Surg Br* 75:546-550, 1993
9. Kumar VP, Satku K, Balasubramaniam P: The role of the long head of biceps brachii in the stabilization of the head of the humerus. *Clin Orthop Relat Res* 172-175, 1989
10. Levy AS, Kelly BT, Lintner SA, et al: Function of the long head of the biceps at the shoulder: Electromyographic analysis. *J Shoulder Elbow Surg* 10:250-255, 2001
11. Neviaser TJ: Arthroscopy of the shoulder. *Orthop Clin North Am* 18:361-372, 1987
12. Pagnani MJ, Deng XH, Warren RF, et al: Role of the long head of the biceps brachii in glenohumeral stability: A biomechanical study in cadavera. *J Shoulder Elbow Surg* 5:255-262, 1996
13. Rodosky MW, Harner CD, Fu FH: The role of the long head of the biceps muscle and superior glenoid labrum in anterior stability of the shoulder. *Am J Sports Med* 22:121-130, 1994
14. Verma N, Drakos M, O'Brien S: Arthroscopic transfer of the long head of the biceps to the conjoint tendon. *Arthroscopy* 21:764, 2005
15. Warner JJ, McMahon PJ: The role of the long head of the biceps brachii in superior stability of the glenohumeral joint. *J Bone Joint Surg Am* 77:366-372, 1995
16. Alpantaki K, McLaughlin D, Karagogeos D, et al: Sympathetic and sensory neural elements in the tendon of the long head of the biceps. *J Bone Joint Surg Am* 87:1580-1583, 2005
17. Becker DA, Cofield RH: Tenodesis of the long head of the biceps brachii for chronic bicipital tendinitis. Long-term results. *J Bone Joint Surg Am* 71:376-381, 1989
18. Berlemann U, Bayley I: Tenodesis of the long head of biceps brachii in the painful shoulder: improving results in the long term. *J Shoulder Elbow Surg* 4:429-435, 1995
19. Dines D, Warren RF, Inglis AE: Surgical treatment of lesions of the long head of the biceps. *Clin Orthop Relat Res* 165-171, 1982
20. Froimson AI, O I: Keyhole tenodesis of biceps origin at the shoulder. *Clin Orthop Relat Res* 245-249, 1975
21. Gill TJ, McIlrvin E, Mair SD, et al: Results of biceps tenotomy for treatment of pathology of the long head of the biceps brachii. *J Shoulder Elbow Surg* 10:247-249, 2001
22. Huffman G, Wolf E: Results in patients with symptomatic degeneration of the long head of the biceps brachii tendon. *Arthroscopy* 19:5, 2003
23. Kelly A, Drakos M, Fealy S, et al: Arthroscopic release of the long head of the biceps tendon: Functional outcome and clinical results. *Am J Sports Med* 33:208-213, 2005
24. Kim SH, Yoo JC: Arthroscopic biceps tenodesis using interference screw: End-tunnel technique. *Arthroscopy* 21:1405, 2005
25. Neviaser R: Lesions of the biceps and tenonitis of the shoulder. *Orthop Clin North Am* 11:343-348, 1980
26. Neviaser TJ, Neviaser RJ, Neviaser JS: The four-in-one arthroplasty for the painful arc syndrome. *Clin Orthop Relat Res* 107-112, 1982
27. Patton WC, McCluskey GM 3rd: Biceps tendinitis and subluxation. *Clin Sports Med* 20:505-529, 2001
28. Carol RE, Hamilton LR: Rupture of the biceps brachii. *J Bone Joint Surg Am* 49:1016, 1968
29. Claessens H, Snoeck H: Tendinitis of the long head of the biceps brachii. *Acta Orthop Belg* 58:124-128, 1972
30. Phillips BB, Canale ST, Sisk TD, et al: Ruptures of the proximal biceps tendon in middle-aged patients. *Orthop Rev* 22:349-353, 1993
31. Osbahr DC, Diamond AB, Speer KP: The cosmetic appearance of the biceps muscle after long-head tenotomy versus tenodesis. *Arthroscopy* 18:483-487, 2002
32. Post M, Benca P: Primary tendinitis of the long head of the biceps. *Clin Orthop Relat Res* 246:117-125, 1989
33. Pfahler M, Branner S, Refior HJ: The role of the bicipital groove in tendopathy of the long biceps tendon. *J Shoulder Elbow Surg* 8:419-424, 1999
34. O'Brien SJ, Pagnani MJ, Fealy S, et al: The active compression test: a new and effective test for diagnosing labral tears and acromioclavicular joint abnormality. *Am J Sports Med* 26:610-613, 1998
35. Bach BR Jr, O'Brien SJ, Warren RF, et al: An unusual neurological complication of the Bristow procedure. A case report. *J Bone Joint Surg Am* 70:458-460, 1988
36. Verma NN, Drakos M, O'Brien SJ: The arthroscopic active compression test. *Arthroscopy* 21:634, 2005
37. Cohen DB, Coleman S, Drakos MC, et al: Outcomes of isolated type II SLAP lesions treated with arthroscopic fixation using a bioabsorbable tack. *Arthroscopy* 22:136-142, 2006