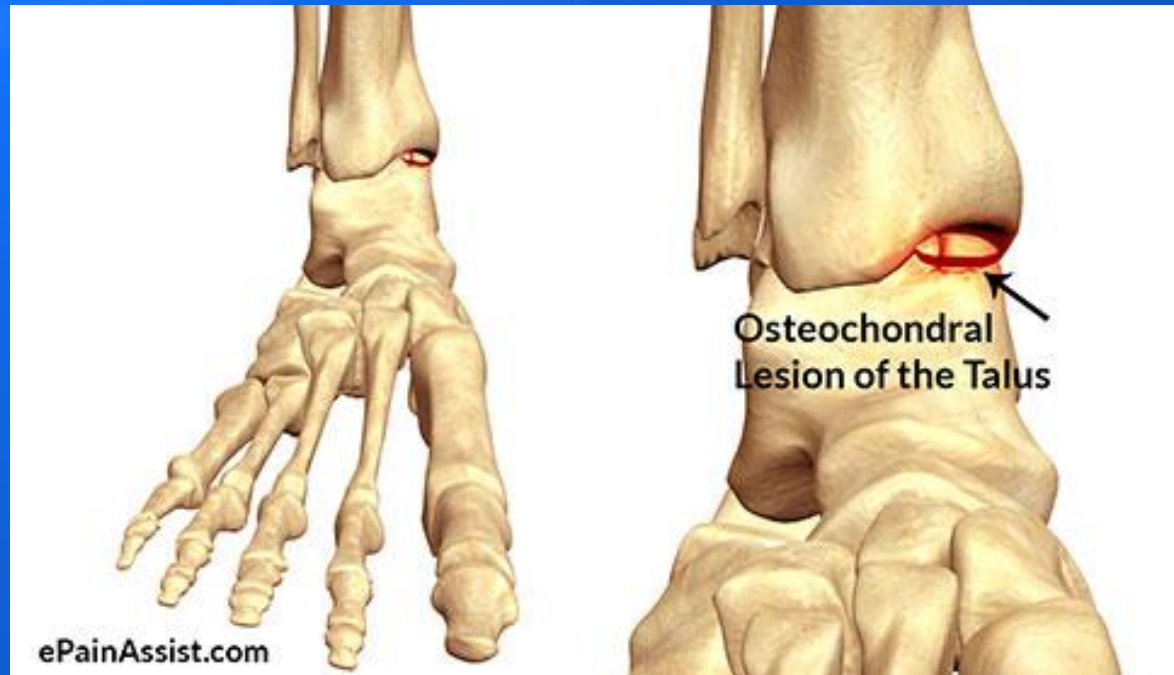


OCL of the Talus



What is an Osteochondral Lesion (OCL) of the Talus?

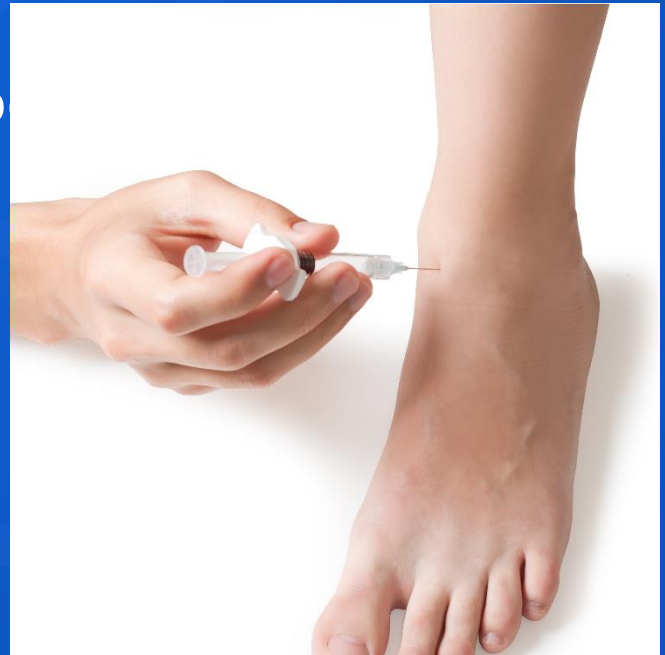- "osteo" – bone
- "chondral" – cartilage



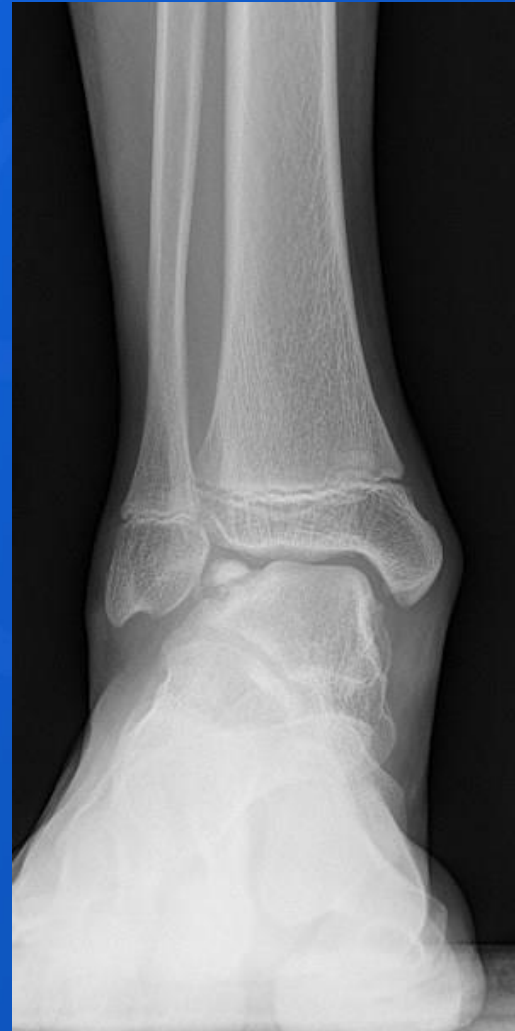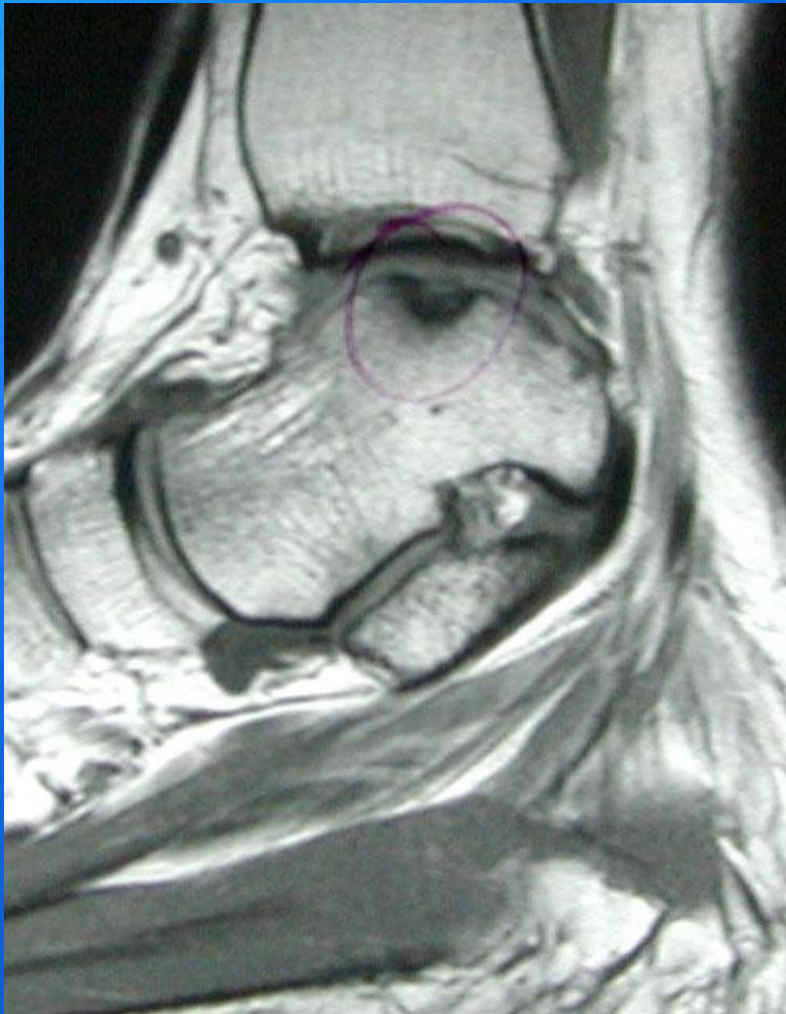Conservative Treatments

■ Conservative Treatment

- Acute nondisplaced lesions
 - Rest, immobilization, activity modification
- Chronic Lesions
 - Anti-inflammatory treatment
 - Ankle Injections
 - Cortisone
 - Monovisc

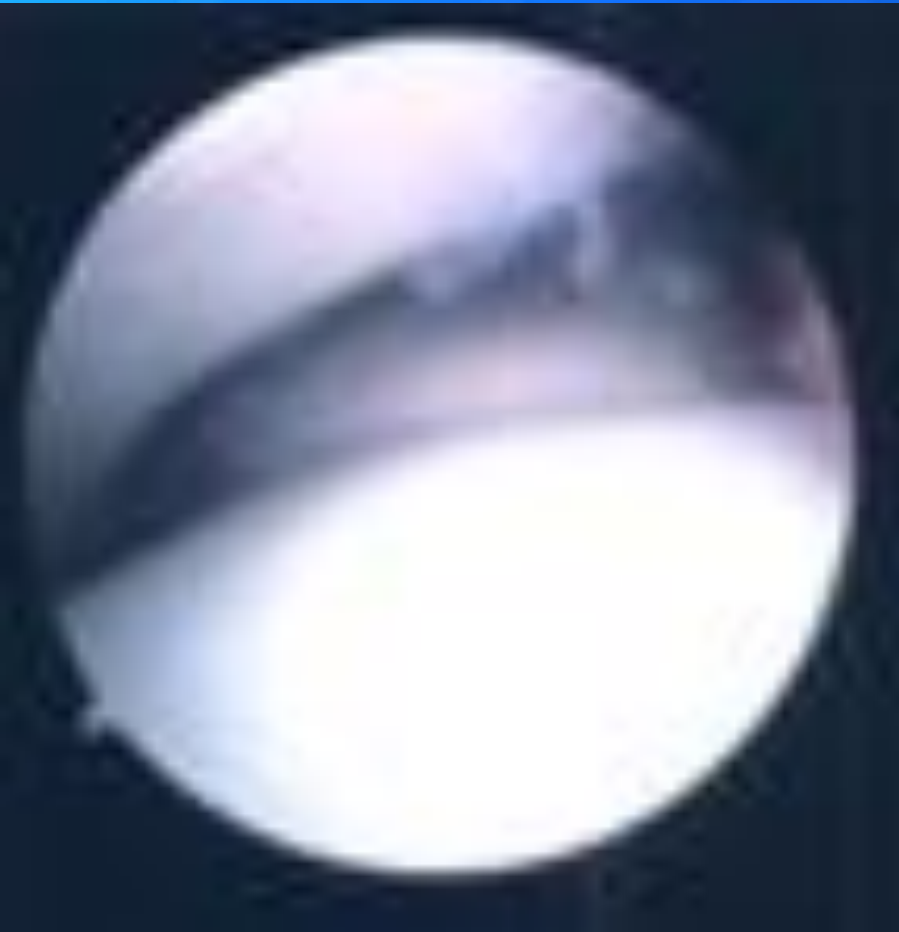

Imaging

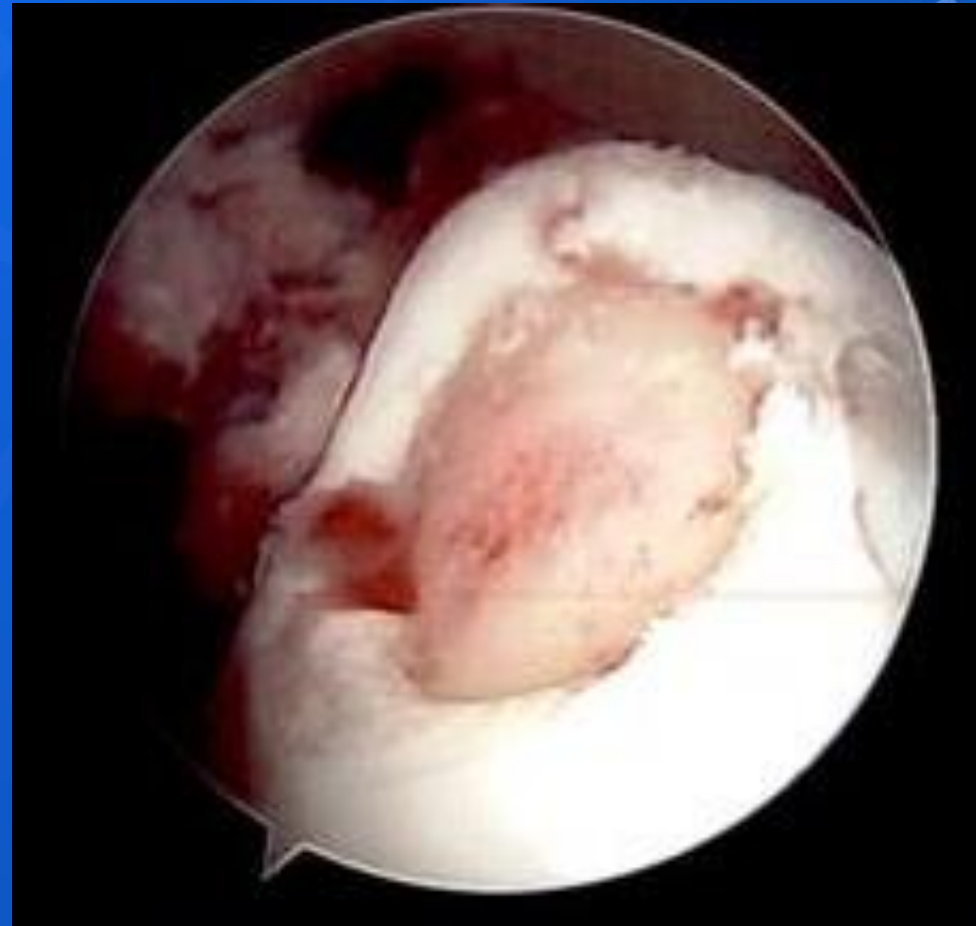


Surgical Treatments - Arthroscopy

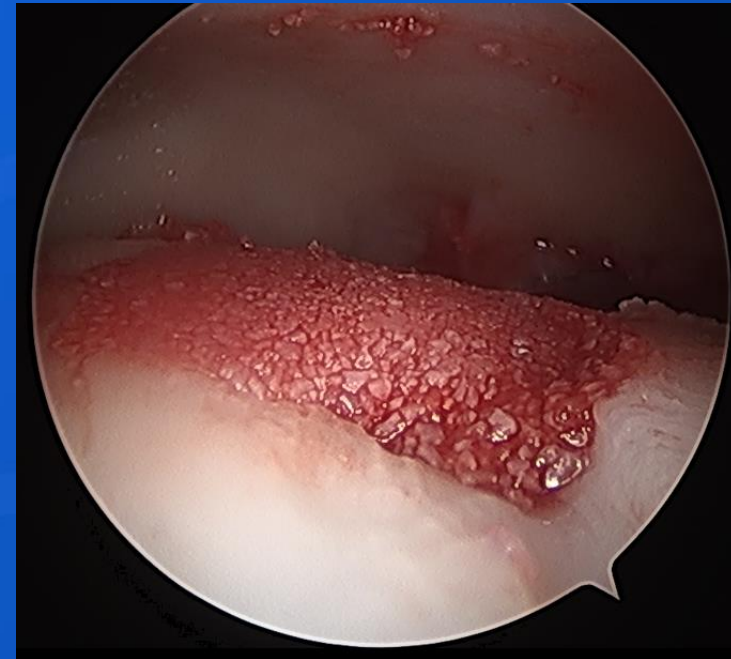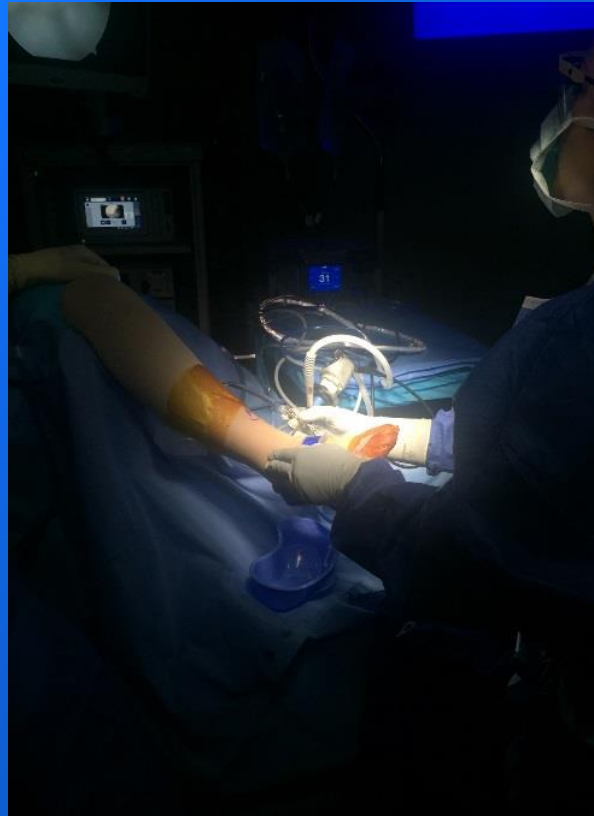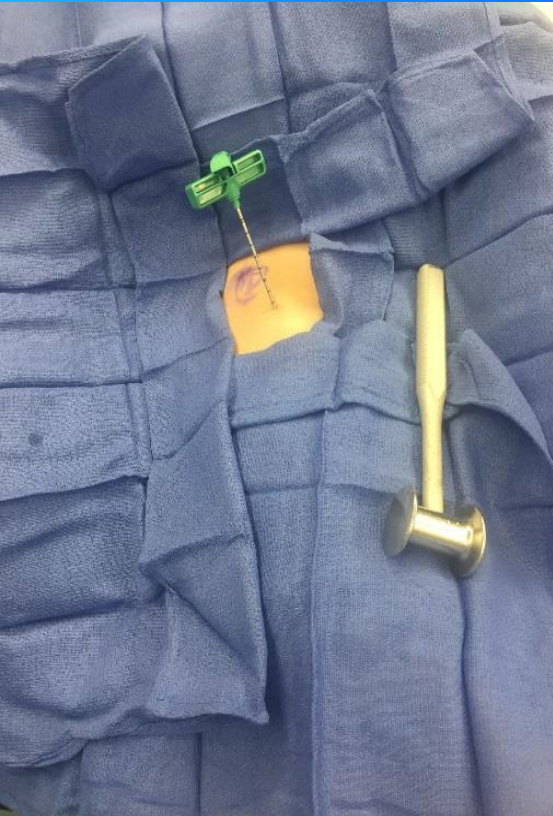Normal Bone



Lesion

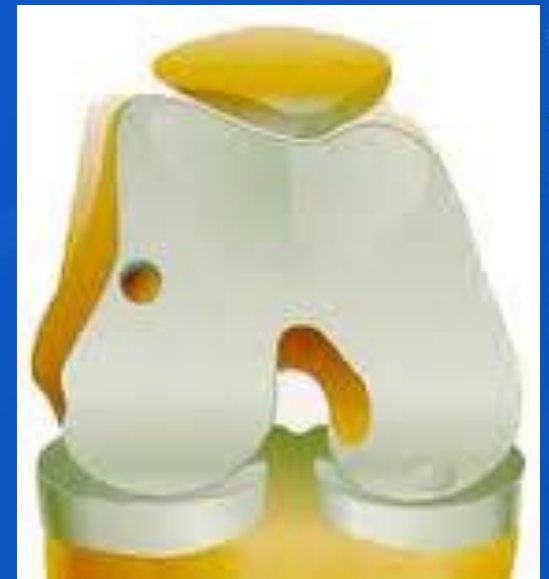
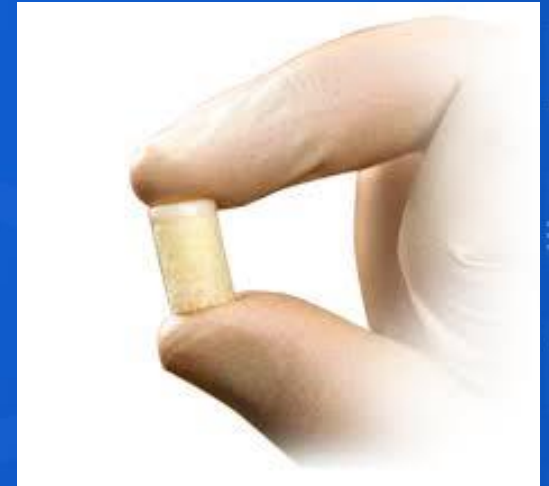
BioCartilage

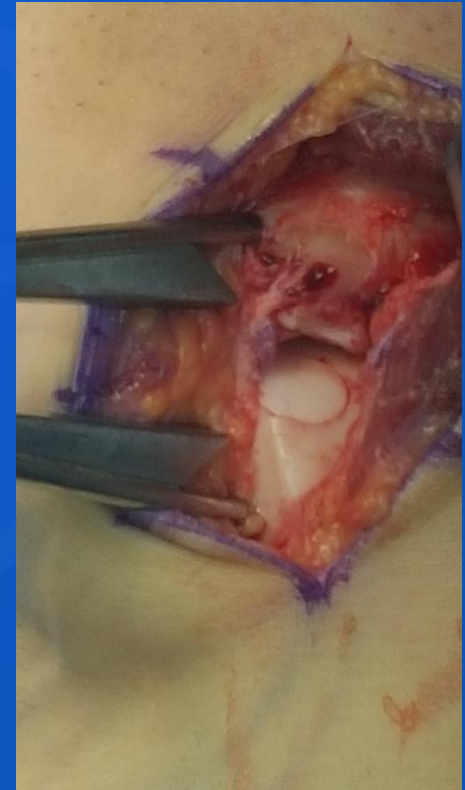
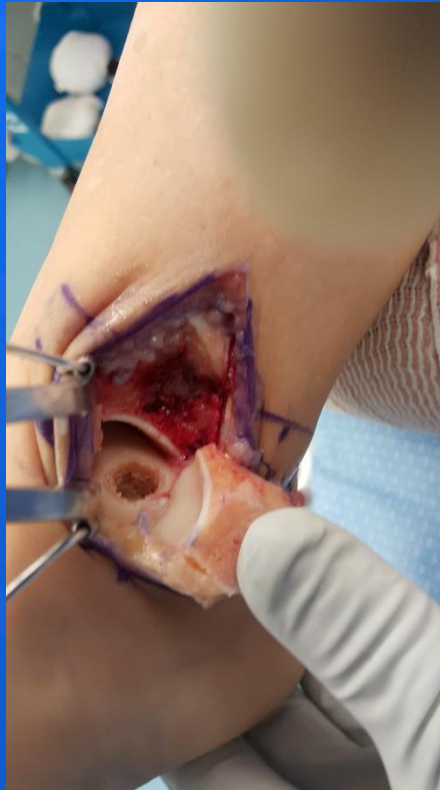
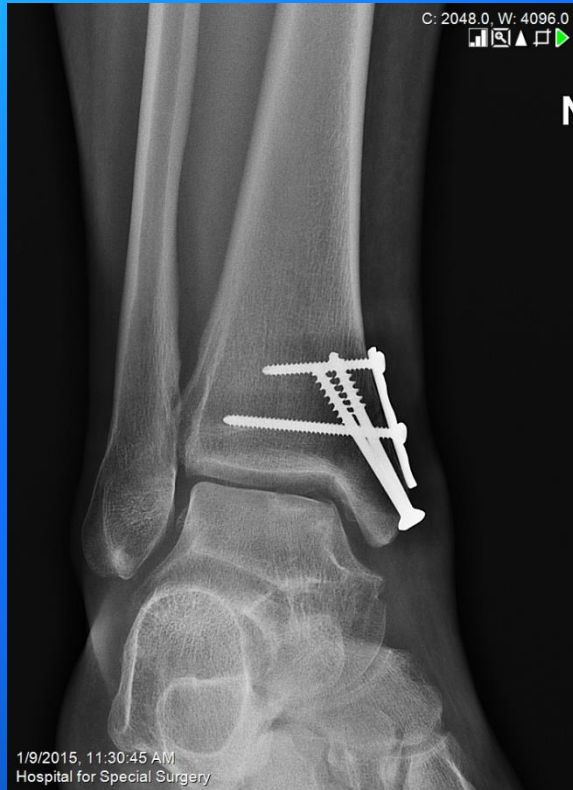OATs

- Osteochondral Autologous Autografts (OATs)
- Recommended for large lesions or failed prior surgery
- Involves taking a bone and cartilage plug from the knee



OATs



Thank You

