

See discussions, stats, and author profiles for this publication at: <https://www.researchgate.net/publication/11559956>

Partial detachment of the deltoid muscle: A case report

Article in *The American Journal of Sports Medicine* · January 2002

Source: PubMed

CITATIONS

13

READS

588

2 authors:



Answorth A Allen

Hospital for Special Surgery

151 PUBLICATIONS 4,658 CITATIONS

SEE PROFILE



Mark C Drakos

Hospital for Special Surgery

130 PUBLICATIONS 1,691 CITATIONS

SEE PROFILE

Some of the authors of this publication are also working on these related projects:



International Consensus Meeting on Cartilage Repair of the Ankle [View project](#)



ACL outcome [View project](#)

The American Journal of Sports Medicine

<http://ajs.sagepub.com/>

Partial Detachment of the Deltoid Muscle : A Case Report

Answorth A. Allen and Mark C. Drakos

Am J Sports Med 2002 30: 133

The online version of this article can be found at:

<http://ajs.sagepub.com/content/30/1/133>

Published by:



<http://www.sagepublications.com>

On behalf of:



[American Orthopaedic Society for Sports Medicine](http://www.aossm.org)

Additional services and information for *The American Journal of Sports Medicine* can be found at:

Email Alerts: <http://ajs.sagepub.com/cgi/alerts>

Subscriptions: <http://ajs.sagepub.com/subscriptions>

Reprints: <http://www.sagepub.com/journalsReprints.nav>

Permissions: <http://www.sagepub.com/journalsPermissions.nav>

Partial Detachment of the Deltoid Muscle

A Case Report

Answorth A. Allen, MD, and Mark C. Drakos*

From the Department of Sports Medicine, Hospital for Special Surgery, New York, New York

There have been few reports of rupture of the deltoid muscle in the literature.^{1,3-5} In each of these reports, the mechanism of injury was associated with either acute or chronic massive rotator cuff tendon failure. In addition, deltoid muscle rupture at its origin is a recognized complication of open rotator cuff surgery.² We report a case of partial detachment of the deltoid muscle without concomitant rotator cuff injury in which the mechanism of injury may be associated with fast-bowling arm movements involved in the sport of cricket.

CASE REPORT

A 31-year-old, right-hand-dominant, professional cricket player (fast bowler) was seen at our department with right shoulder pain that had lasted for 4 months. He reported no specific history of trauma, but he had pain over the lateral border of the acromion after bowling competitively. This limited his ability to play professional cricket. Examination of his right shoulder revealed prominence at the posterolateral corner of the acromion compared with the left shoulder. Partial detachment of approximately 20% of the posterior deltoid muscle was obvious. He had tenderness on palpation of the posterior aspect of the deltoid muscle. The patient had full active and passive range of motion of the shoulder, with no evidence of shoulder instability or impingement. He had 5/5 strength of the supraspinatus, subscapularis, and external rotator muscles. He had 4/5 strength of shoulder abduction. No neurologic deficits were noted.

Roentgenograms revealed a normal type I acromion. There was a heterotrophic calcification at the posterolateral corner of the acromion (Fig. 1). Magnetic resonance imaging confirmed the diagnosis of a partial detachment of the deltoid muscle (Fig. 2). There was also evidence of

myositis ossificans in the substance of the deltoid muscle at the posterolateral corner of the acromion. The tendons of the rotator cuff were extremely well developed and were normal on MRI. There was no evidence of stress fracture or any other bony lesions. Tendinitis of the deltoid muscle tendon was ruled out as well. No other shoulder abnormalities were observed.

The patient took indomethacin (75 mg) for 15 days. He also started a supervised rehabilitation program. He made a full recovery and was able to return to pain-free bowling after 8 weeks.

DISCUSSION

The mechanisms involved in partial detachment of the deltoid muscle have yet to be fully elucidated. Yamaguchi et al.⁵ reported that repeated hydrocortisone injections may be one of the causative factors leading to rupture of

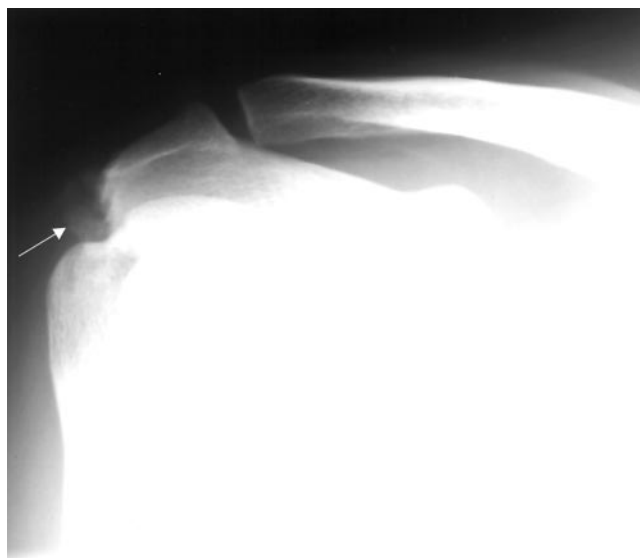


Figure 1. Calcification at the posterolateral corner of the acromion (arrow).

* Address correspondence and reprint requests to Mark Drakos, Research Assistant, Hospital for Special Surgery, 535 East 70th Street, New York, NY 10021.

No author or related institution has received any financial benefit from research in this study.

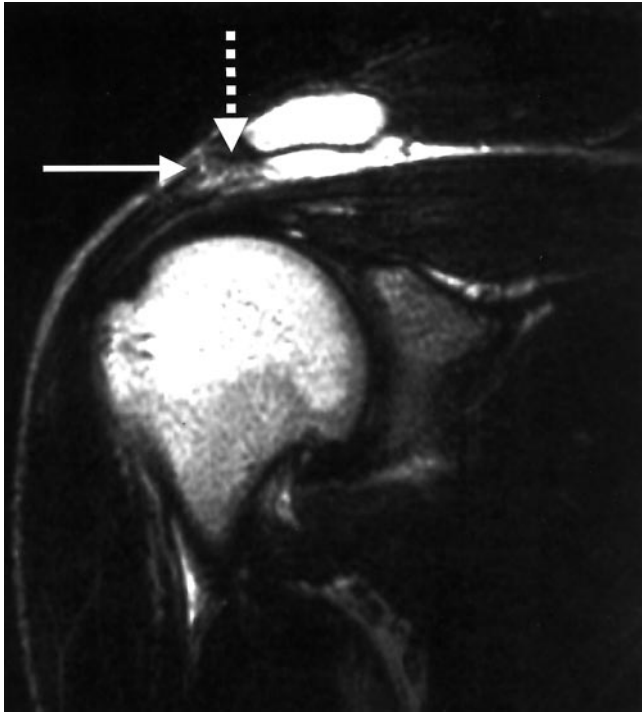

Figure 2. Partial deltoid muscle detachment (solid arrow) and heterotrophic bone in the deltoid muscle (dotted arrow).

the deltoid muscle. Our patient had no such history. There are a few reports of spontaneous deltoid muscle detachment in patients with chronic, massive rotator cuff tears.^{1,3-5} In this patient population, functional disability,

loss of strength, and decreased range of motion are the predominant complaints. Persistent shoulder pain is usually a secondary complaint. Our patient had a normal rotator cuff. This is the first report to our knowledge of spontaneous deltoid muscle detachment from a sports-related injury in a young, active patient.

The “windmill” action of cricket generates pitch speeds of 95 mph or more. This action is clockwise when observed in a right shoulder. There has been no analysis of this motion in the literature to date. It is quite different from other throwing and swinging sports such as Jai Alai and fast-pitch softball, in which the windup is in a counterclockwise direction when viewed from a right shoulder. We think that the windmill action of the bowling motion places significant forces on the deltoid muscle and can lead to partial deltoid muscle detachment. Pain and weakness are significant features of this condition. Our patient responded to nonsteroidal antiinflammatory drugs and physical therapy. Surgical intervention was not recommended in this case.

REFERENCES

1. Blazar PE, Williams GR, Iannotti JP: Spontaneous detachment of the deltoid muscle origin. *J Shoulder Elbow Surg* 7: 389–392, 1998
2. Matsen FA III, Arntz CT: Rotator cuff tendon failure, in Rockwood CA Jr, Matsen FA III (eds): *The Shoulder*. Philadelphia, WB Saunders, 1990, pp 647–677
3. Morisawa K, Yamashita K, Asami A, et al: Spontaneous rupture of the deltoid muscle associated with massive tearing of the rotator cuff. *J Shoulder Elbow Surg* 6: 556–558, 1997
4. Panting AL, Hunter MH: Spontaneous rupture of the deltoid [abstract]. *J Bone Joint Surg* 65B: 518, 1983
5. Yamaguchi K, Ito N, Eto M, et al: Rupture of the deltoid muscle belly with tear of the rotator cuff: A case report. *Seikei Geka* 44: 1663–1666, 1993