

The use of polyvinyl alcohol hydrogel implants in the lesser metatarsal heads. Is it safely doable? A cadaveric study

Cesar de Cesar Netto^{a,*}, Alexandre Leme Godoy-Santos^b, Taylor N. Cabe^a, Lauren E. Roberts^a, Thos Harnroongroj^a, Jonathan Deland^a, Mark Drakos^a

^a Department of Orthopaedics, Foot and Ankle Surgery, Hospital for Special Surgery, 523 East 72nd Street, New York, NY 10023, USA

^b Department of Orthopaedics, Foot and Ankle Surgery, University of Sao Paulo (USP), St. Ovidio Pires de Campos 333, Sao Paulo, SP, Brazil

ARTICLE INFO

Article history:

Received 16 October 2018

Received in revised form 19 December 2018

Accepted 27 December 2018

Keywords:

Lesser metatarsal

Lesser metatarsophalangeal joints

Metatarsal heads

Polyvinyl hydrogel

Interposition arthroplasty

ABSTRACT

Background: The use of synthetic polyvinyl alcohol hydrogel (PVAH) implants for treatment of lesser toe metatarsophalangeal joint (MTPJ) arthritis is promising and currently limited by the size of implants available. The primary objective of this cadaveric study was to investigate the maximum drilling size and largest PVAH implant dimension that could be safely introduced while still preserving an intact bone rim of the lesser metatarsal heads.

Methods: Height and width of all lesser metatarsals were measured on CT and during anatomic dissection. Sequential reaming of the second to fourth metatarsals was performed. Maximum reaming size, largest implant inserted, and failure of the metatarsal head were recorded. Metatarsal head sizes were compared and a multiple regression analysis evaluated measurements that influenced maximum drilling and implant size.

Results: CT and anatomical measurements demonstrated significant correlation (ICC range, 0–0.85). Mean values for height and width of the metatarsal heads were respectively: second (14.9 mm and 9.9 mm), third (14.8 mm and 8.8 mm), fourth (14.0 mm and 8.7 mm) and fifth (12.3 mm and 9.3 mm). All the second, third and fourth metatarsal heads could be safely drilled up to 7.5 mm, preserving an intact bone rim. At 80% of the time, the heads could be safely drilled up to 8.0 mm. Height of the metatarsal heads was the only factor to significantly influence the size of maximum reaming and implant introduced. In respectively 20%, 40% and 50% of the second, third, and fourth metatarsal heads, neither 8 mm nor 10 mm PVAH implants could be used.

Conclusions: Our cadaveric study found that the even though the majority of the lesser metatarsal heads could be safely drilled up to 8 mm, the smallest PVAH implant size currently available in most countries (8 mm) could be inserted in most of the second, but only in about half of the third and fourth metatarsal heads. The remaining bone rim around inserted implants was considerably thin, usually measuring less than 1 mm. In order to optimize the use PVAH in lesser metatarsal heads, smaller implant options are needed.

© 2019 European Foot and Ankle Society. Published by Elsevier Ltd. All rights reserved.

1. Introduction

Lesser toe and metatarsophalangeal disorders are frequent, and their treatment represent a frequent challenge for Foot and Ankle surgeons. The number of surgical procedures for treatment of these pathologies is huge, with substantial associated economic burden [1].

Arthritic degeneration of the lesser metatarsophalangeal joint (MTPJ) can occur as a complication of trauma [2], chronic joint overload [3], hallux valgus and transfer metatarsalgia [4], plantar plate disruption and joint instability [5], Freiberg's infraction [6,7], and as a complication of surgical treatment of lesser toe deformities [1,8].

Surgical treatment options for symptomatic arthritis of the lesser MTPJ are scarce. The alternatives available in the literature, depending on the severity of the disease and the association of joint instability, include but are not restricted to: open or arthroscopic joint debridement [7,9], dorsiflexion osteotomy of the metatarsal head [10], interposition arthroplasty [9,11–13], plantar plate repair [14–17], fusion [18], and metatarsal head

* Corresponding author.

E-mail addresses: cesardecesarnetto@gmail.com (C. de Cesar Netto), alexandrelemegodoy@usp.br (A.L. Godoy-Santos), taylorcabe29@gmail.com (T.N. Cabe), lauren.roberts@medportal.ca (L.E. Roberts), ultradeutsch@gmail.com (T. Harnroongroj), delandj@hss.edu (J. Deland), drakosm@hss.edu (M. Drakos).

resection [19,20]. Multiple MTPJ interposition arthroplasties have been proposed in the literature [21], with overall good outcomes [22–25]. Different interposition materials can be used, such as the MTPJ dorsal capsule [26–29], periosteum [30], fascia lata [31], tendon autograft and allograft [11,32–35], acellular dermal matrix [26,36,37], and silicone implants [13].

Recently, the use of polyvinyl alcohol hydrogel (PVAH) implants has become popular in the treatment of end-stage hallux rigidus and first MTPJ arthritis, with good reported short-term outcomes [38–41]. The currently off label use of these same implants in the treatment of lesser MTPJ arthritis is a reality and can potentially represent an important surgical alternative. However, the size of the implants currently commercialized in most of the countries include only the 8 mm and 10 mm in diameter size as they were primarily designed with the first metatarsal in mind. This poses a significant limitation and relative contraindication for their use in the substantially lower dimensions of the lesser metatarsal heads.

The primary objective of this cadaveric study was to assess the maximum drilling size and largest PVAH implant dimension that could be safely introduced into each lesser metatarsal head while still preserving an intact bone rim of the metatarsal head. The secondary objective was to evaluate the average height and width of the lesser metatarsal heads using Computed tomography (CT) scans and true anatomical measurements.

Our hypothesis was that the currently available sizes of PVAH implants would not allow safe utilization of the implants in the lesser metatarsal heads and that CT measurements of lesser metatarsal heads sizing would significantly correlate with intraoperative anatomical measurements.

2. Material and methods

This study was approved by our Institutional Review Board. Ten thawed below knee fresh-frozen cadaveric specimens were used, six females and four males, with a mean age of 48.3 (range, 25–61) years. None of the specimens were found to have any noticeable deformity or pathology of the foot and ankle, neither evidence of prior surgery.

2.1. CT scans and CT measurements

The specimens were first placed in a posterior splint with the foot plantigrade and the ankle joint positioned in neutral dorsiflexion. CT images were acquired in a CT scan (Biograph, Siemens, Munich, Germany) with 0.6 mm slice thickness and $0.5 \times 0.5 \text{ mm}^2$ in-plane pixel dimensions, 140 kV and 140 mA.

The acquired three-dimensional datasets were converted into axial, sagittal and coronal image slices, that were then transferred and analyzed in a dedicated software (Materialise Mimics, Materialise, Leuven, Belgium). Image annotations were erased to ensure anonymity, and each imaging study was assigned with a random and unique identification number. Two independent and blinded Fellowship-Trained Foot and Ankle surgeon observers assessed each imaging study and measured the height and width of the lesser metatarsal heads. The height was measured at the center portion of the head, and the width in its thinnest portion (Fig. 1). One of the observers repeated these same measurements two weeks later, respecting the washout period, to minimize recall bias.

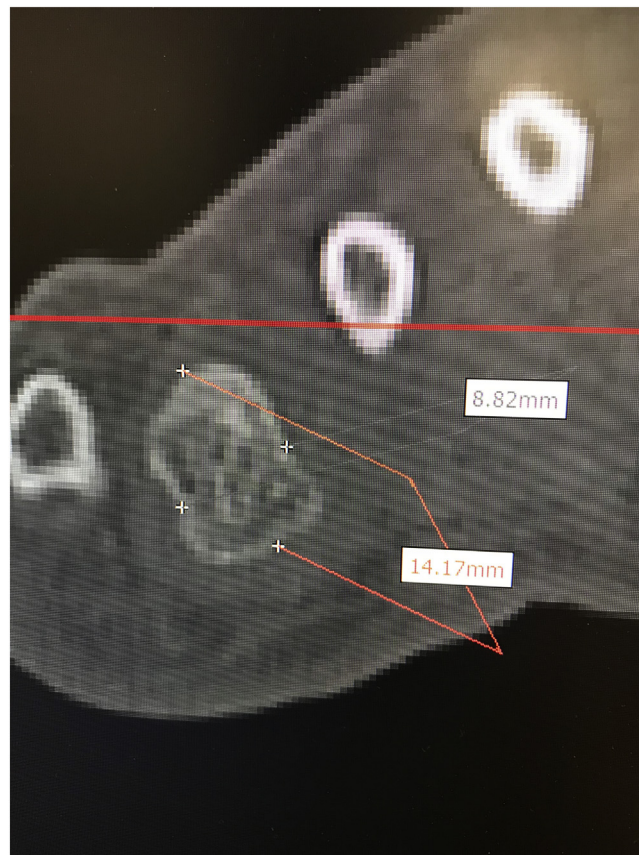

Fig. 1. Example of computed tomography (CT) measurement of the height and width of the fourth metatarsal head (coronal plane).

2.2. Surgical dissection and clinical measurements

All surgical procedures were performed by a third Fellowship-trained Foot and Ankle surgeon independent observer, with 15 years of surgical experience. Some highlights of the surgical and measurement technique are presented in Fig. 2. The forefoot soft tissue was amputated in an elliptical fashion, at the level of the MTPJ, completely exposing the heads of the first, second, third, fourth and fifth metatarsals. The dorsal, plantar, medial and lateral aspects of the lesser metatarsal heads were marked, and height and width were measured with a precision marking digital caliper (precision 0.02 mm).

Following the surgical technique guidelines for the PVAH available in the market (Cartiva[®], Cartiva Inc., Georgia, US), a 2 mm guide-wire was introduced into the head of the second metatarsal with the help of the concave end of the provided positioner centrally in the head and perpendicular to the articular surface. The technique was slightly modified for its use in the lesser metatarsals for the purpose of this study. Because of the cadaveric nature of the study and the need for multiple consecutive drilling of each metatarsal head, the guide wire was advanced further into the metatarsal shaft to minimize its toggling during the multiple drillings. The correct positioning of the guide wire was checked under fluoroscopy. Sequential drilling of the second metatarsal head, starting with a 4.5 mm cannulated drill and progressing with 0.5 mm increments was then performed, until a maximum drill bit diameter of 10 mm was achieved or until one the surrounding bone rim was violated. For the 8 mm and 10 mm drilling, the drill bit provided in the PVAH implant kit was used. The thickness of the surrounding bone rim (four quadrants: dorsal, plantar, medial and lateral) was measured with the precision digital caliper after each 1 mm drilling increment, from 6 mm to 10 mm or until the bone rim was completely violated by the drill in one of its quadrants. If the 8 mm mark could be reached without compromising the bone rim, the 8 mm PVAH implant was inserted using the provided

introducer tube. The integrity of the bone rim was reassessed after introduction of the implant, making sure it was still intact and that the implant was stable. Similarly, if the 10 mm drilling could be safely achieved without compromising the rim, the 10 mm PVAH implant was inserted with the provided introducer tube and followed by reevaluation of the bone rim integrity and stability of the implant. The exact same procedure was then repeated for the third and fourth metatarsals.

For each metatarsal, maximum drilling diameter, largest implant inserted (8 mm or 10 mm) and destruction of bone rim quadrants were recorded.

2.3. Statistical analysis

Data analysis was performed using JMP Pro version 12.2.0 (SAS Institute, Marlow-Buckinghamshire, UK). Measurements were initially evaluated for normality with the Shapiro–Wilk test. Descriptive statistics was used to report the average dimensions of the metatarsal heads (anatomical and CT measurements), largest drill bit diameter, and bone rim measurements. Inter-method correlation between CT and anatomical measurements was evaluated by intraclass correlation coefficient (ICC), considering the amount by which bias, and interaction factors can influence the ICC. Correlations of 0.81–0.99 were considered almost perfect; 0.61–0.80, substantial; 0.41–0.60, moderate; 0.21–0.40, fair; and slight if equal or inferior to 0.20 [42]. Metatarsal head heights and widths were compared by Wilcoxon each pair analysis. Multiple regression analysis was used to evaluate which specific measurement influenced the maximum drilling diameter and implant size could be successfully achieved without damaging the bone rim. A partition prediction model was then used to provide a threshold values for the relationship between the dimensions of the lesser metatarsal heads and the maximum size of the drilling achieved and PVAH implanted. p-Values of less than 0.05 were considered significant.

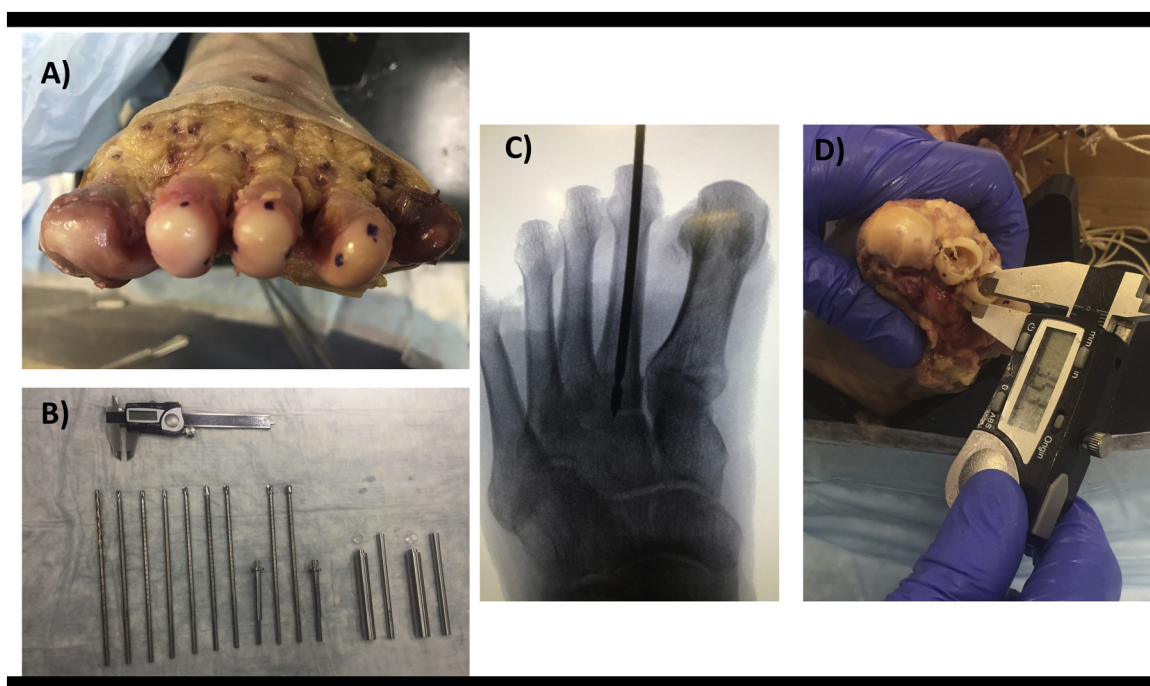


Fig. 2. Surgical procedures, progressive reaming, and anatomical measurements. (A) Metatarsal heads exposed following elliptical amputation of the forefoot at the level of the metatarsophalangeal joints (MTPJ). Dorsal, plantar, medial and lateral edges marked. (B) Surgical setting with drill bits, introducers and implants. (C) Fluoroscopic anteroposterior image demonstrating a well-positioned guide wire intramedullary in the second metatarsal. (D) Bone rim measurement with a precision digital caliper.

Table 1
Summary of anatomical and averaged CT measurements for the lesser metatarsal heads.

	Second metatarsal head				Third metatarsal head				Fourth metatarsal head				Fifth metatarsal head			
	Mean	95% CI	Minimum	Maximum	Mean	95% CI	Minimum	Maximum	Mean	95% CI	Minimum	Maximum	Mean	95% CI	Minimum	Maximum
Height Anatomical measurement	15.4 mm	16.0 mm – 14.8 mm	14.4 mm	16.7 mm	14.6 mm	14.0 mm – 15.3 mm	13.6 mm	16.2 mm	13.8 mm	13.0 mm – 14.6 mm	12.1 mm	15.9 mm	12.3 mm	11.5 mm – 13.1 mm	11.2 mm	15.3 mm
CT measurement	14.0 mm	14.9 mm – 13.0 mm	12.4 mm	15.7 mm	14.2 mm	13.3 mm – 15.1 mm	12.0 mm	16.0 mm	14.2 mm	13.3 mm – 15.2 mm	11.5 mm	15.9 mm	12.3 mm	11.5 mm – 13.1 mm	11.0 mm	14.8 mm
Width Anatomical measurement	11.2 mm	10.6 mm – 11.9 mm	9.6 mm	12.4 mm	9.5 mm	9.1 mm – 9.9 mm	8.6 mm	10.4 mm	9.7 mm	9.1 mm – 10.2 mm	8.2 mm	10.5 mm	9.2 mm	8.6 mm – 9.7 mm	7.9 mm	10.2 mm
CT measurement	10.6 mm	9.8 mm – 11.3 mm	8.9 mm	12.0 mm	9.0 mm	8.6 mm – 9.5 mm	7.9 mm	10.1 mm	9.2 mm	8.7 mm – 9.8 mm	8.1 mm	10.3 mm	9.7 mm	9.1 mm – 10.2 mm	8.8 mm	11.0 mm

CI, Confidence interval; CT, Computed tomography; mm, millimeters.

3. Results

A summary for the anatomical measurements and averaged CT measurements is presented in Table 1 and Fig. 3.

The intraobserver agreement for CT measurements of lesser metatarsal head dimensions was substantial for both the height (ICC, 0.73) and width (ICC, 0.69). The interobserver agreement for CT measurements was found to be moderate for height (ICC, 0.57) and substantial for width (ICC, 0.69). The intermethod correlation between anatomical and CT measurements of lesser metatarsal head dimensions were found to be almost perfect for height (ICC, 0.87) and moderate for width (ICC, 0.59). Parallelism plots for intermethod correlation of metatarsal heads height and width measurements are presented in Fig. 4.

Graphical plots demonstrating comparison of averaged anatomical measurements for the different lesser metatarsal heads is presented in Fig. 5. The second metatarsal head was found to have significantly increased height when compared to the fourth ($p=0.0046$) and fifth metatarsals ($p=0.0006$), but similar dimensions to the third metatarsal head ($p=0.053$). The height of the third metatarsal head was also found to be significantly higher than the fifth ($p=0.0013$), but similar to the fourth metatarsal ($p=0.0635$). The height of the fourth metatarsal head was significantly increased when compared to the fifth ($p=0.0036$).

Regarding the width, the second metatarsal head was also found to be significantly wider than the third ($p=0.0015$), fourth ($p=0.0053$) and fifth metatarsals ($p=0.0010$). The other lesser metatarsals all were found to have similar width (all p -values >0.05).

The height of each metatarsal head was always larger than the width for all metatarsals in all cadaveric specimens. The mean difference between the height and width, when considering all metatarsal heads, was 4.15 mm (95% CI, 3.6–4.7, $p < 0.0001$). When evaluating each metatarsal head in isolation, the mean differences between height and width were respectively: 4.2 mm (95% CI, 3.4–5.0, $p < 0.0001$) for the second metatarsal, 5.2 mm (95% CI, 4.5–5.8, $p < 0.0001$), 4.15 (95% CI, 3.3–5.0, $p < 0.0001$) for the third metatarsal, 4.1 mm (95% CI, 3.3–5.0, $p < 0.0001$) for the fourth metatarsal and 3.1 mm (95% CI, 2.2–4.0, $p < 0.0001$) for the fifth metatarsal.

Graphical plot representation for percentages of maximum drilling size and PVAH implant inserted is presented in Fig. 6. All the second, third and fourth metatarsal heads could be safely drilled up to 7.5 mm, preserving an intact bone rim. At 80% of the time, the heads could be safely drilled up to 8.0 mm. However, 20% of the second metatarsal heads, 40% of the third metatarsal heads and 50% of the fourth metatarsal heads failed to accommodate the smallest available PVAH implant (8 mm) without having breakage of at least one of the bone rim quadrants. The 10 mm PVAH implant was successfully inserted in only 20% of the second metatarsal heads, preserving an intact bone rim, but could not be inserted in any of the third or fourth metatarsal heads.

The only factor that was found to significantly influence the maximum drilling size that could be successfully achieved was the height of the metatarsal heads measured anatomically ($p=0.0016$). Neither metatarsal number (second, third or fourth) nor the width of the metatarsal heads were not found to significantly influence the maximum drilling size. Metatarsal height was also the only factor influencing the size of the PVAH implant that could be inserted, when measured on both CT images ($p < 0.0001$) and clinically ($p=0.013$). Number and width of the metatarsal heads again did not influence the size of the implant inserted.

The partition prediction model demonstrated that when the height of the lesser metatarsal heads was measured above 15.7 mm anatomically and 15.5 mm on CT scan images, the chances of maximizing drilling and the PVAH implant inserted were increased.

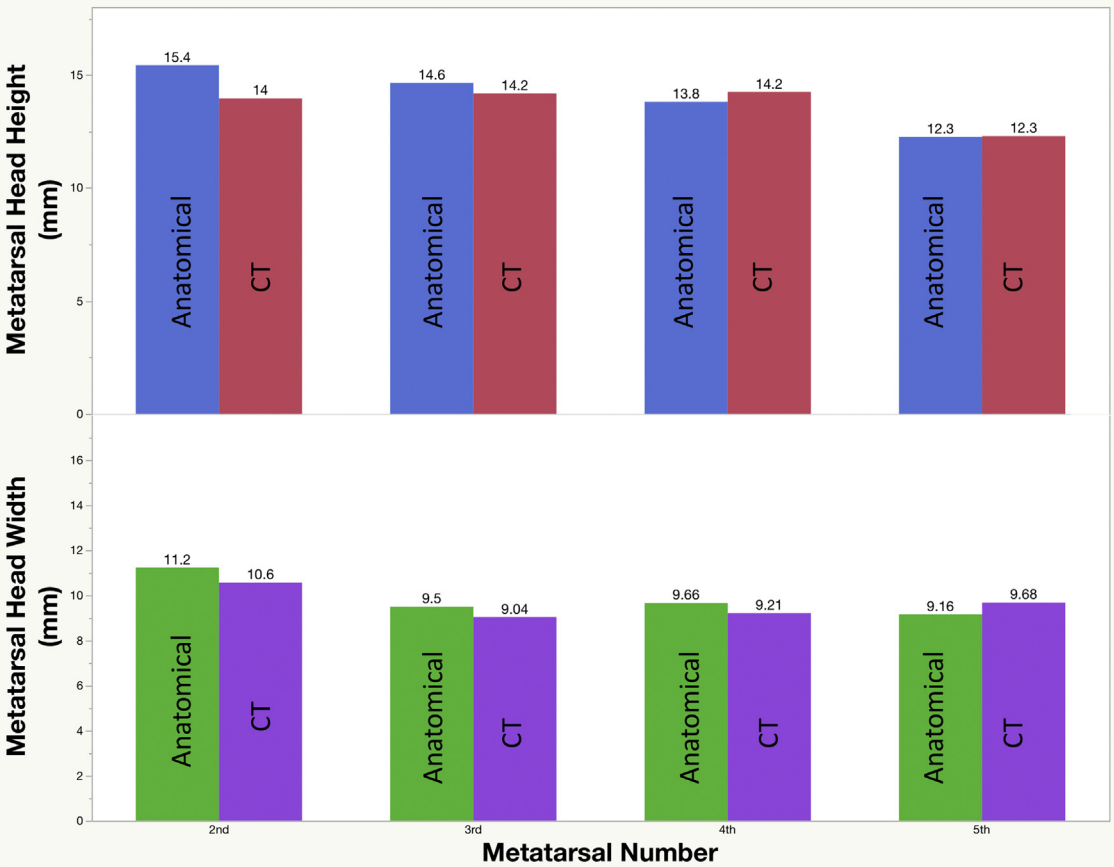


Fig. 3. Graphical plot representation of averaged values for anatomical and computed tomography (CT) measurements for height and width of the lesser metatarsals.

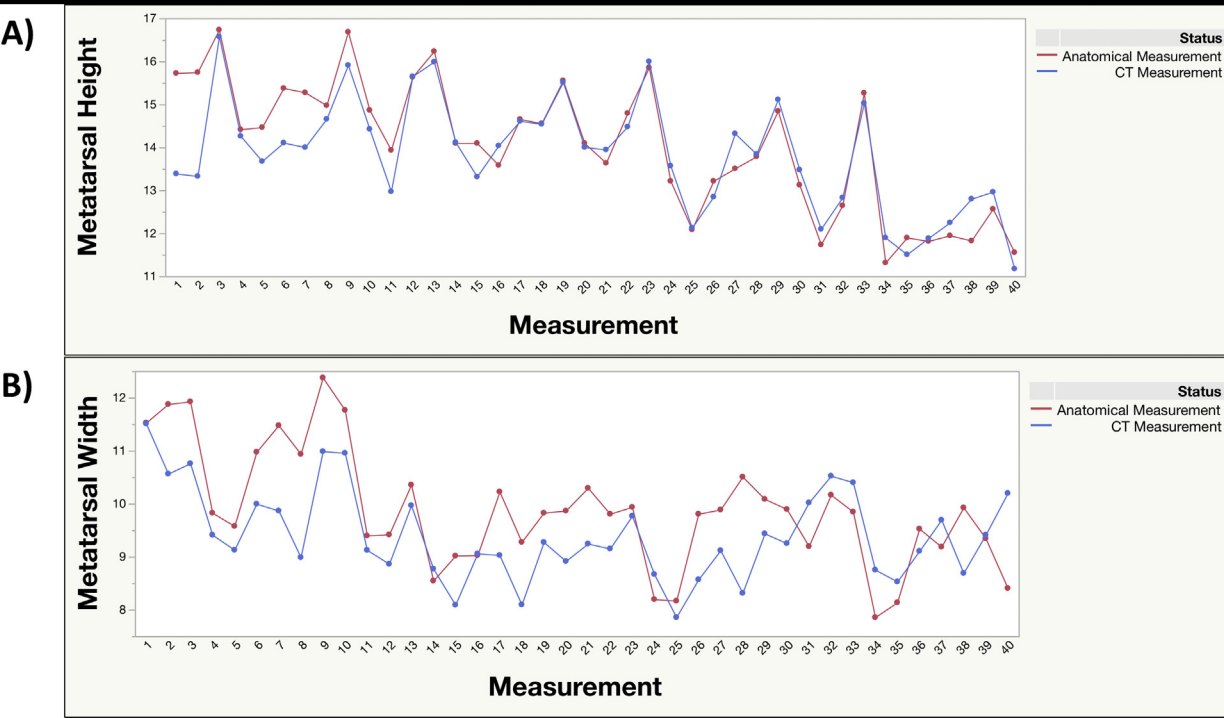


Fig. 4. Parallelism graphical plots for intermethod correlation of metatarsal heads height and width measurements.

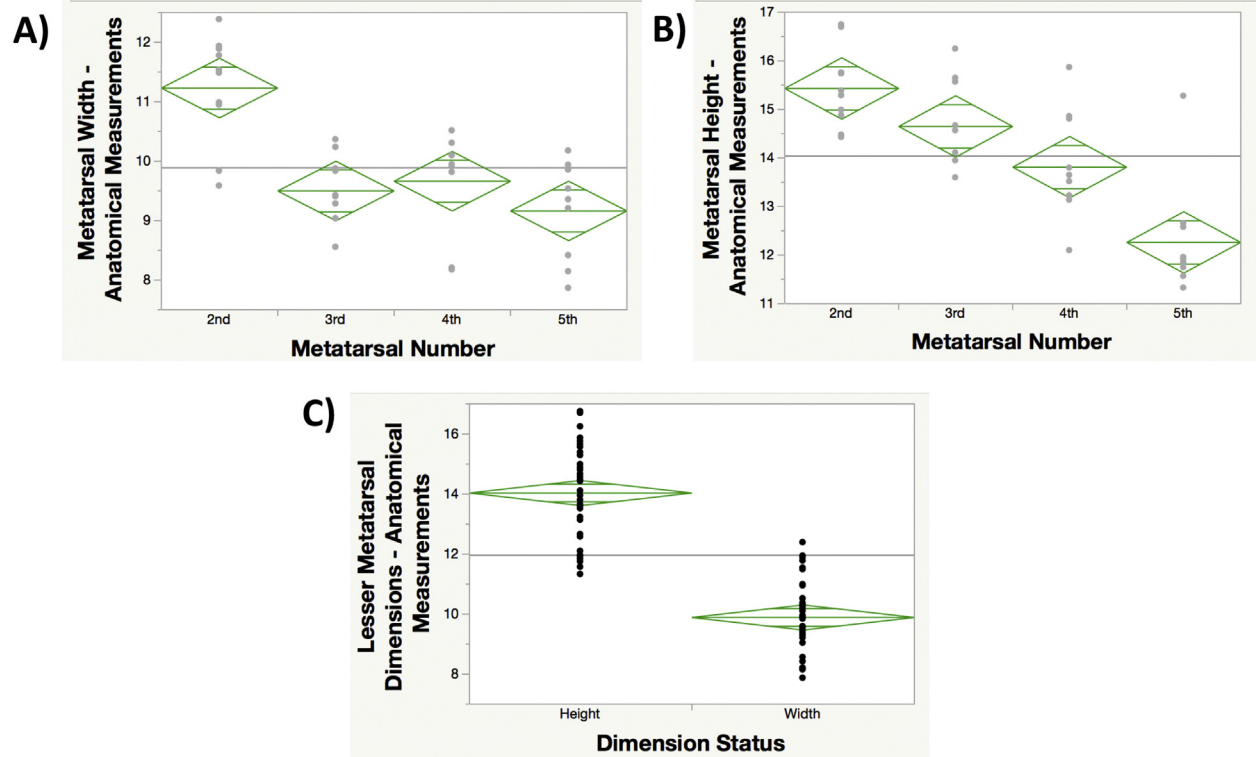


Fig. 5. Graphical plots for comparison of averaged anatomical measurements for different lesser metatarsal heads: (A) height; (B) width; (C) height versus width.

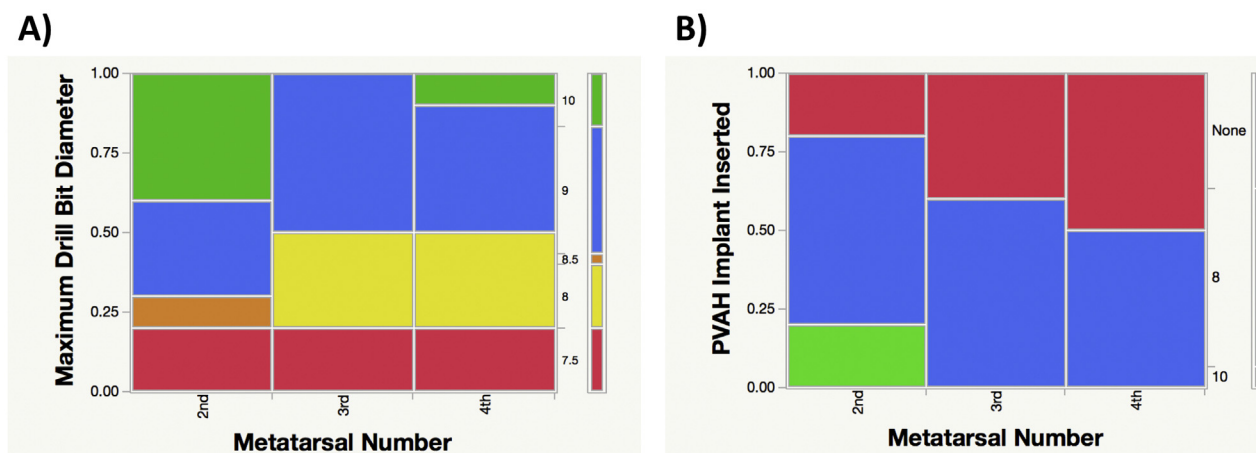


Fig. 6. Graphical plot representation of percentages of maximum drilling size (A) and polyvinyl alcohol hydrogel (PVAH) implant inserted (B) for the second, third and fourth metatarsal heads.

A summary of the measurements for bone rim thickness (medial, lateral, plantar and dorsal quadrants) of the lesser metatarsal heads, following each 1 mm increment in the drilling size, is presented in Table 2. The medial quadrant was usually the thinnest for most lesser metatarsal heads following each progressive drilling, and the first to fail in 40% (4/10) of the second metatarsal heads, and 60% (6/10) of the third and fourth metatarsal heads. The second most common bone rim quadrant to fail was the lateral, occurring in 20% (2/10) of the second metatarsal heads, and 30% (3/10) of the third and fourth metatarsal heads (Fig. 7). The dorsal bone rim quadrant was violated in only 10% (1/10) of the second, third and fourth metatarsal heads. Similarly, the plantar bone rim quadrant failed in only 10% of the second and fourth metatarsal heads, with no failures seen in the third metatarsal.

4. Discussion

To the best of the author's knowledge, this is the first study to investigate the use of PVAH implants in the lesser MTPJ. We found that the height of the metatarsal heads influenced the size of maximum reaming and implant introduced and that in respectively 20%, 40% and 50% of the second, third, and fourth metatarsal heads, neither the 8 mm nor 10 mm PVAH implants could be used.

We demonstrated that the overall height measurements for the lesser metatarsal heads progressively decrease from second to fifth, but their width is pretty similar when excluding the wider second metatarsal head. These findings were similar to results previously reported in the literature [43,44]. The measurements for height were significantly increased when compared to the width, for all lesser metatarsal heads, explaining why most of the violations of the bone rim following progressive drilling occurred either in the medial or lateral aspects of the metatarsal heads. Interestingly, the only measurement found to influence the maximum drilling and implant size that could be used in the lesser metatarsals was the height of the metatarsal head. Our study also demonstrated that both preoperative CT scan evaluation and anatomical intraoperative measurements of lesser metatarsal heads sizing can be reliably used, with adequate intermethod correlation. The small differences found in the measurements when comparing anatomical and CT examinations could be explained by inherent inaccuracies of each one of the methods, with possible minor variabilities on the choice of anatomical landmarks used by the observers.

More importantly, our study found that even though most of the lesser metatarsal heads could be drilled up to 8 mm, while preserving an intact bone rim of the metatarsal head, the thickness of the medial and lateral walls was noticeable thin, with measurements around 1 mm for the second metatarsal, and less than a millimeter for the third and fourth metatarsal heads, putting in risk the insertion of an 8 mm PVAH implant. Considering the lower dimensions of the lesser metatarsal heads when compared to the first metatarsal, if one would consider a 2 mm bone rim as ideal to optimize the safety of the procedure and stability of the PVAH implant, accordingly to our study results, on average, most of the second, third and fourth metatarsal heads could be drilled up to 6 mm, preserving adequate a bone rim thicker than 2 mm. However, the thinnest bone rim quadrant measured after 6 mm drilling was 1.1 mm, on the medial aspect of the fourth metatarsal head. If a 1 mm bone rim was considered a safe threshold, all lesser metatarsals heads evaluated in our study would be then considered safely drilled with the 6 mm drill bit.

The medial aspect of the lesser metatarsal heads was noticeably the thinnest during the progressive drilling and usually the first quadrant to fail. Even though the surgical guidelines proposed by manufacturer of the PVAH implant were followed, because of the cadaveric nature of the study and the planning for repetitive and

progressive drilling in each lesser metatarsal, the surgical technique was slightly modified, what could have influenced the results of our study. Instead of introducing the guide wire only a few centimeters into the metatarsal head to allow the drilling, we aimed to advance the guide wire into the metatarsal shaft, allowing increased stability during the progressive drilling, minimizing toggling of the guide wire and subsequent injury to the metatarsal head bone rim. We have observed that there is frequently a lateral offset of the center of the metatarsal head relative to the axis of the metatarsal shaft, meaning that the metatarsal shaft axis line was usually in a medial position when compared to the metatarsal head center line (Fig. 8), what could have influenced the entry-point of the guide wires, forcing them to be in a relatively medial positioning, explaining in part the reason why the medial aspect of the metatarsal heads was frequently the thinnest and the first to be violated. The report by Galli et al. demonstrated some comparable findings in regard to the anatomy of the lesser metatarsal heads [45]. In their study with 10 cadaveric specimens, the authors assessed which portion of the lesser metatarsal head was penetrated during K-wire fixation of the lesser toes across the MTPJ and into the metatarsal shaft. They found that in 79% of the specimens, the wire would penetrate the metatarsal head in a medial position, relatively to the center of the metatarsal head. This concept should be considered during the surgical planning and potential clinical use of PVAH implants in the lesser metatarsal heads, to avoid aiming the guide wire into the metatarsal shaft, maintaining a centered position and protecting the medial aspect of the bone rim.

The use of PVAH implants in the treatment of first MTPJ arthritis has recently demonstrated successful results [40,41], promising short-term clinical outcomes [38], and a 96% implant survivorship after a mean follow-up of 5.4 years, with significant improvement in the first MTPJ range of motion [39]. In the treatment of lesser MTPJ arthritis, where preservation of joint mobility is paramount and surgical alternatives are scarce [9,11–13,20,46], the use PVAH implants, even though still off label, can potentially represent an interesting surgical alternative. However, our study demonstrated that one of the current limitations in the use of PVAH implants in the lesser metatarsal heads is for sure the available implant sizing. The current sizes commercialized in most countries, 8 mm and 10 mm, accordingly to our study results, would not provide enough options for their safe use in the treatment of lesser metatarsal pathologies. Even though the 8 mm implant was successfully inserted in 80% of the second metatarsal heads and approximately 50% of the third and fourth metatarsal heads, the surrounding bone rim, especially along the medial and lateral aspects of the implant, was considerably thin. Additional options of smaller implant sizes (5 mm, 6 mm and 7 mm) are needed to optimize the use of PVAH in the lesser metatarsal heads.

Our study has some important limitations to be considered. First, the use of cadaveric specimens could have influenced the results of the study. The characteristics of the cadaveric bone quality is different from live tissue, and results regarding adequate bone rim, maximum drilling size and implant inserted could be different in real patients. The surgical approach and technique would also be different in a clinical setting, where considerably less amount of soft tissue dissection and metatarsal head exposure would be possible, probably influencing drilling and PVAH insertion process. Second, none of the cadaveric specimens used had arthritic findings of the lesser MTPJ. The presence of degenerative disease in those joints could potentially increase the technical difficulty of the procedure and influence the results of the study. Third, even though a systematic approach was used to perform both the CT and anatomical measurements of the metatarsal head sizes and bone rim thickness, there is always some variation involved in the process. Fourth, the progressive

Table 2

Summary of the measurements for bone rim thickness of the lesser metatarsal heads.

		Medial rim				Lateral rim				Dorsal rim				Plantar rim			
		Mean	95% CI	Minimum	Maximum	Mean	95% CI	Minimum	Maximum	Mean	95% CI	Minimum	Maximum	Mean	95% CI	Minimum	Maximum
After 6 mm drilling	Second metatarsal head	2.7 mm	2.2 mm – 3.1 mm	1.7 mm	3.8 mm	2.6 mm	1.9 mm – 3.2 mm	1.4 mm	4.0 mm	4.2 mm	3.6 mm – 4.9 mm	3.2 mm	6.2 mm	4.3 mm	3.8 mm – 4.8 mm	3.3 mm	5.5 mm
	Third metatarsal head	2.1 mm	1.5 mm – 2.6 mm	1.2 mm	3.5 mm	2.2 mm	1.7 mm – 2.7 mm	1.1 mm	3.3 mm	4.2 mm	3.6 mm – 4.8 mm	2.4 mm	5.0 mm	3.5 mm	2.9 mm – 4.1 mm	2.1 mm	4.9 mm
	Fourth metatarsal head	1.8 mm	1.4 mm – 2.2 mm	1.1 mm	3.3 mm	2.0 mm	1.7 mm – 2.4 mm	1.2 mm	2.9 mm	3.8 mm	3.1 mm – 4.6 mm	3.0 mm	5.8 mm	2.7 mm	2.4 mm – 3.0 mm	2.3 mm	3.4 mm
After 7 mm drilling	Second metatarsal head	1.8 mm	1.3 mm – 2.2 mm	1.0 mm	3.0 mm	2.2 mm	1.6 mm – 2.9 mm	1.0 mm	3.8 mm	3.8 mm	3.3 mm – 4.4 mm	2.9 mm	5.6 mm	3.2 mm	2.6 mm – 3.8 mm	2.2 mm	4.6 mm
	Third metatarsal head	1.4 mm	1.2 mm – 1.6 mm	0.9 mm	2.0 mm	1.7 mm	1.3 mm – 2.1 mm	0.8 mm	2.5 mm	3.6 mm	2.9 mm – 4.3 mm	2.0 mm	4.9 mm	2.7 mm	2.1 mm – 3.4 mm	1.4 mm	3.9 mm
	Fourth metatarsal head	1.1 mm	0.8 mm – 1.5 mm	0.8 mm	1.1 mm	1.3 mm	1.0 mm – 1.6 mm	0.6 mm	2.2 mm	2.8 mm	2.1 mm – 3.5 mm	1.7 mm	4.3 mm	1.9 mm	1.5 mm – 2.3 mm	1.3 mm	3.1 mm
After 8 mm drilling	Second metatarsal head	1.0 mm	0.6 mm – 1.5 mm	0.4 mm	2.2 mm	1.4 mm	0.8 mm – 1.9 mm	0 mm	2.9 mm	2.8 mm	1.8 mm – 3.7 mm	0 mm	4.9 mm	2.6 mm	2.1 mm – 2.6 mm	1.9 mm	4.0 mm
	Third metatarsal head	0.7 mm	0.2 mm – 1.2 mm	0 mm	2.2 mm	0.9 mm	0.7 mm – 1.2 mm	0.3 mm	1.5 mm	2.8 mm	2.0 mm – 3.5 mm	1.4 mm	4.0 mm	2.0 mm	1.5 mm – 2.6 mm	1.0 mm	3.2 mm
	Fourth metatarsal head	0.7 mm	0.3 mm – 1.2 mm	0 mm	1.9 mm	0.9 mm	0.6 mm – 1.3 mm	0 mm	1.6 mm	2.3 mm	1.7 mm – 3.0 mm	1.3 mm	3.9 mm	1.5 mm	0.8 mm – 2.1 mm	0.4 mm	3.2 mm
After 9 mm drilling	Second metatarsal head	0.7 mm	0.1 mm – 1.3 mm	0 mm	2.4 mm	1.2 mm	0.6 mm – 1.8 mm	0.4 mm	2.7 mm	2.9 mm	2.1 mm – 3.7 mm	2.0 mm	4.6 mm	2.0 mm	1.1 mm – 2.8 mm	0.5 mm	3.5 mm
	Third metatarsal head	0.8 mm	0 mm – 1.6 mm	0 mm	2.1 mm	0.6 mm	0.2 mm – 1.9 mm	0.2 mm	1.0 mm	2.7 mm	2.0 mm – 3.5 mm	1.7 mm	3.5 mm	1.8 mm	1.1 mm – 2.6 mm	1.0 mm	2.7 mm
	Fourth metatarsal head	0.6 mm	0 mm – 1.2 mm	0 mm	1.7 mm	0.7 mm	0.4 mm – 1.0 mm	0.3 mm	1.2 mm	2.4 mm	1.6 mm – 3.3 mm	1.1 mm	3.4 mm	1.3 mm	0.5 mm – 1.3 mm	0.5 mm	2.5 mm
After 10 mm drilling	Second metatarsal head	0.4 mm	0 mm – 0.9 mm	0 mm	1.5 mm	0.9 mm	0.3 mm – 1.6 mm	0 mm	2.2 mm	2.2 mm	1.5 mm – 3.0 mm	1.1 mm	3.3 mm	1.4 mm	0.5 mm – 2.2 mm	0 mm	2.5 mm
	Third metatarsal head	0.3 mm	0 mm – 1.3 mm	0 mm	1.3 mm	0.3 mm	0 mm – 0.7 mm	0 mm	0.7 mm	1.8 mm	0.2 mm – 3.3 mm	0 mm	3.3 mm	1.7 mm	0.6 mm – 2.8 mm	0.7 mm	2.4 mm
	Fourth metatarsal head	0.3 mm	0 mm – 1 mm	0 mm	1.2 mm	0.5 mm	0 mm – 1.1 mm	0 mm	1.2 mm	1.7 mm	0.3 mm – 3.1 mm	0 mm	3.0 mm	0.9 mm	0.1 mm – 1.7 mm	0 mm	1.8 mm

CI, Confidence interval; mm, millimeters.

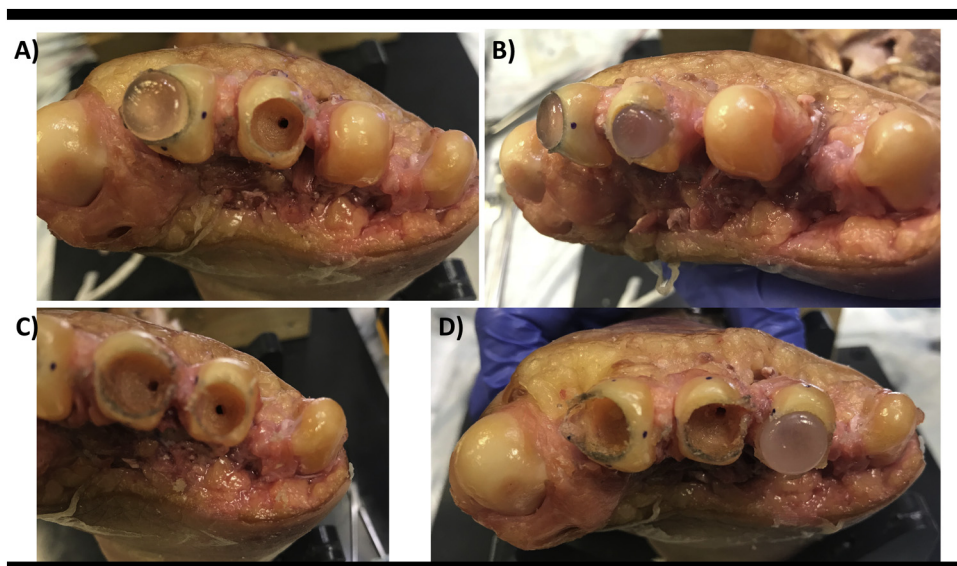


Fig. 7. Examples of surgical findings in a cadaveric specimen. (A) Polyvinyl alcohol hydrogel (PVAH) implant inserted into the second metatarsal head with preserved bone rim and a very thin lateral bone rim following 8-millimeter (mm) drilling of the third metatarsal head. (B) Violated lateral bone rim of the third metatarsal head following insertion of the 8 mm PVAH. (C) Thin medial bone rim following 8-millimeter (mm) drilling of the fourth metatarsal head. (D) Destroyed medial bone rim of the fourth metatarsal head following insertion of the 8 mm PVAH.

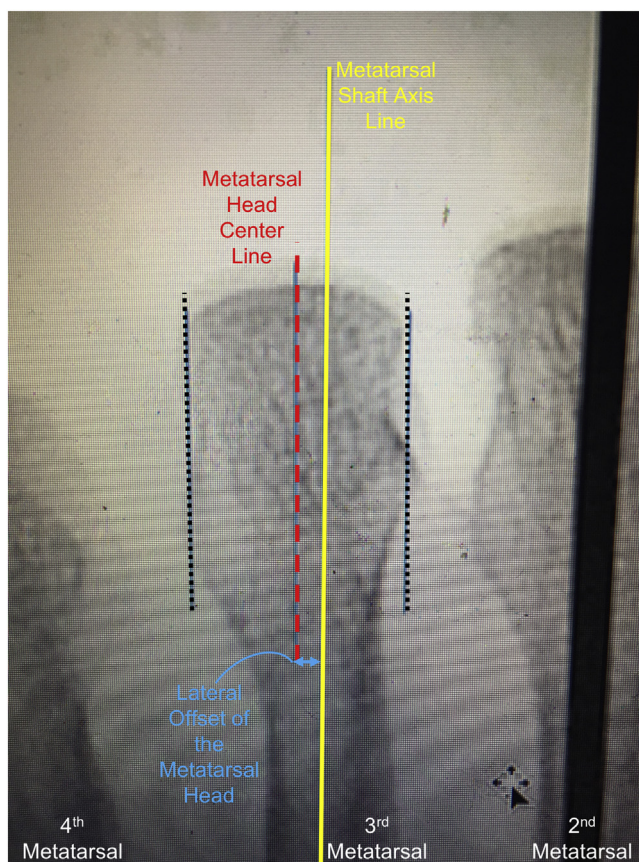


Fig. 8. Fluoroscopic anteroposterior image of the third metatarsal of a cadaveric specimen demonstrating an example of lateral offset of the metatarsal head relative to the axis of the metatarsal shaft. Metatarsal head center line is laterally positioned in relation to the metatarsal shaft axis line.

drilling technique utilized might have increased the amount of bone resected in the metatarsal, as result of some minor toggling and drilling Kerf. Finally, even though we had a relatively small number of cadaveric specimens and no sample size calculation was performed, we believe that due to the descriptive nature of the

study, the number of specimens utilized was enough to achieve the its objectives.

Concluding, in our cadaveric study we described the mean height and width of the lesser metatarsal heads and demonstrated that both CT scan and anatomical measurements can be reliably performed.

We found that increased metatarsal height measurements were associated with a wider drilling size and PVAH implant inserted. The smallest implant size currently available in most countries (8 mm) could be inserted in most of the second metatarsal heads, and in about half of the third and fourth metatarsal heads. However, the remaining bone rim around the implant was considerably thin, with thickness measurements mostly under 1 mm. We also found that during progressive drilling, the medial and lateral aspects of the bone rim were usually the ones to fail. In order to preserve adequate bone rim and optimize the use PVAH in lesser metatarsal heads, smaller implant options are needed.

Conflicts of interest

The author(s) received no financial support for the authorship, and/or publication of this article. Cartiva Inc.[®] donated the implants and introducer kits. None of the authors have financial relationships with the company. There are no other conflicts of interest.

Dr. Cesar Netto reports: Paid consultancy for a company or supplier (CurveBeam, Ossio). Stock or stock options in a company or supplier (CurveBeam).

Dr. Mark Drakos reports: Dr. Drakos reports personal fees and other from Extremity Medical, personal fees from Fast Form, and personal fees from Pitusan 360 outside the submitted work.

References

- [1] Phisitkul P. Managing complications of lesser toe and metatarsophalangeal joint surgery. *Foot Ankle Clin* 2018;23:145–56.
- [2] Silver SA, Mizel MS. Open reduction and internal fixation of a simultaneous lesser metatarsal fracture and MPJ dislocation. *Foot Ankle Int* 2000;21:520–1.
- [3] Milgrom C, Finestone A, Sharkey N, Hamel A, Mandes V, Burr D, et al. Metatarsal strains are sufficient to cause fatigue fracture during cyclic overloading. *Foot Ankle Int* 2002;23:230–5.
- [4] Lee KT, Park YU, Jegal H, Young KW, Kim JS, Lim SY. Osteoarthritis of the second metatarsophalangeal joint associated with hallux valgus deformity. *Foot Ankle Int* 2014;35:1329–33.
- [5] Nery C, Coughlin MJ, Baumfeld D, Mann TS. Lesser metatarsophalangeal joint instability: prospective evaluation and repair of plantar plate and capsular insufficiency. *Foot Ankle Int* 2012;33:301–11.
- [6] Carmon MR, Rees RJ, Blundell CM. Current concepts review: Freiberg's disease. *Foot Ankle Int* 2009;30:167–76.
- [7] Cho J, Kim JR, Lee WC. Degenerative osteoarthritis of the second metatarsophalangeal joint: second toe rigidus. *Int Orthop* 2013;37:1863–9.
- [8] Mueller CM, Boden SA, Boden AL, Maidman SD, Cutler A, Mignemi D, et al. Complication rates and short-term outcomes after operative hammertoe correction in older patients. *Foot Ankle Int* 2018;39:681–8.
- [9] Lui TH. Arthroscopic interpositional arthroplasty of the second metatarsophalangeal joint. *Arthrosc Tech* 2016;5:e1333–8.
- [10] Helix-Gordano M, Randier E, Frey S, Piclet B, French association of foot surgery (AFCP). Treatment of Freiberg's disease by Gauthier's dorsal cuneiform osteotomy: retrospective study of 30 cases. *Orthop Traumatol Surg Res* 2015;101:S221–5.
- [11] Liao CY, Lin AC, Lin CY, Chao TK, Lu TC, Lee HM. Interpositional arthroplasty with palmaris longus tendon graft for osteonecrosis of the second metatarsal head: a case report. *J Foot Ankle Surg* 2015;54:237–41.
- [12] Ozkan Y, Ozturk A, Ozdemir R, Aykut S, Yalcin N. Interpositional arthroplasty with extensor digitorum brevis tendon in Freiberg's disease: a new surgical technique. *Foot Ankle Int* 2008;29:488–92.
- [13] Cracchiolo 3rd A, Kitaoka HB, Leventen EO. Silicone implant arthroplasty for second metatarsophalangeal joint disorders with and without hallux valgus deformities. *Foot Ankle* 1988;9:10–8.
- [14] Nery C, Coughlin MJ, Baumfeld D, Raduan FC, Mann TS, Catena F. Prospective evaluation of protocol for surgical treatment of lesser MTP joint plantar plate tears. *Foot Ankle Int* 2014;35:876–85.
- [15] Hsu RY, Barg A, Nickisch F. Lesser metatarsophalangeal joint instability: advancements in plantar plate reconstruction. *Foot Ankle Clin* 2018;23:127–43.
- [16] Flint WW, Macias DM, Jastifer JR, Doty JF, Hirose CB, Coughlin MJ. Plantar plate repair for lesser metatarsophalangeal joint instability. *Foot Ankle Int* 2017;38:234–42.
- [17] Finney FT, Lee S, Scott J, Irwin TA, Holmes JR, Talusan PG. Biomechanical evaluation of suture configurations in lesser toe plantar plate repairs. *Foot Ankle Int* 2018;39:836–42.
- [18] Hirose CB, Gamboa JT, Coughlin MJ. Concomitant first and second metatarsophalangeal arthrodesis for intractable second metatarsophalangeal joint pain. *Foot Ankle Int* 2014;35:825–8.
- [19] Ozkul E, Gem M, Alemdar C, Arslan H, Bogatekin F, Kisin B. Results of two different surgical techniques in the treatment of advanced-stage Freiberg's disease. *Indian J Orthop* 2016;50:70–3.
- [20] Horita M, Nishida K, Hashizume K, Nasu Y, Saiga K, Nakahara R, et al. Outcomes of resection and joint-preserving arthroplasty for forefoot deformities for rheumatoid arthritis. *Foot Ankle Int* 2018;39:292–9.
- [21] Ferguson CM, Ellington JK. Operative technique: interposition arthroplasty and biological augmentation of hallux rigidus surgery. *Foot Ankle Clin* 2015;20:513–24.
- [22] Kennedy JG, Chow FY, Dines J, Gardner M, Bohne WH. Outcomes after interposition arthroplasty for treatment of hallux rigidus. *Clin Orthop Relat Res* 2006;445:210–5.
- [23] Lau JT, Daniels TR. Outcomes following cheilectomy and interpositional arthroplasty in hallux rigidus. *Foot Ankle Int* 2001;22:462–70.
- [24] Sanhudo JA, Gomes JE, Rodrigo MK. Surgical treatment of advanced hallux rigidus by interpositional arthroplasty. *Foot Ankle Int* 2011;32:400–6.
- [25] Vulcano E, Chang AL, Solomon D, Myerson M. Long-term follow-up of capsular interposition arthroplasty for hallux rigidus. *Foot Ankle Int* 2018;39:1–5.
- [26] Aynardi MC, Atwater L, Dein EJ, Zahoor T, Schon LC, Miller SD. Outcomes after interpositional arthroplasty of the first metatarsophalangeal joint. *Foot Ankle Int* 2017;38:514–8.
- [27] Enriquez Castro JA, Guevara Hernandez G, Estevez Diaz G. Interposition arthroplasty as treatment of osteochondritis of the second metatarsal head. A case report. *Acta Ortop Mex* 2008;22:259–62.
- [28] Hamilton WG, O'Malley MJ, Thompson FM, Kovatis PE. Roger Mann Award 1995. Capsular interposition arthroplasty for severe hallux rigidus. *Foot Ankle Int* 1997;18:68–70.
- [29] Schenk S, Meizer R, Kramer R, Aigner N, Landsiedl F, Steinboeck G. Resection arthroplasty with and without capsular interposition for treatment of severe hallux rigidus. *Int Orthop* 2009;33:145–50.
- [30] Abdul W, Hickey B, Perera A. Functional outcomes of local pedicle graft interpositional arthroplasty in adults with severe Freiberg disease. *Foot Ankle Int* 2018;39:1290–300. doi:http://dx.doi.org/10.1177/1071100718786494 Epub 2018 Aug 17.
- [31] Givissis P, Symeonidis P, Christodoulou A, Pournaras J. Interposition arthroplasty of the first metatarsophalangeal joint with a fascia lata allograft. *J Am Podiatr Med Assoc* 2008;98:160–3.
- [32] Miyamoto W, Takao M, Innami K, Yasui Y, Matsushita T. Technique tip: interposition of extensor digitorum longus after resection arthroplasty of lesser metatarsophalangeal joints for rheumatoid forefoot deformity. *Foot Ankle Int* 2011;32:211–4.
- [33] Barca F. Tendon arthroplasty of the first metatarsophalangeal joint in hallux rigidus: preliminary communication. *Foot Ankle Int* 1997;18:222–8.
- [34] Coughlin MJ, Shurnas PJ. Soft-tissue arthroplasty for hallux rigidus. *Foot Ankle Int* 2003;24:661–72.
- [35] Thomas D, Thordarson D. Rolled tendon allograft interposition arthroplasty for salvage surgery of the hallux metatarsophalangeal joint. *Foot Ankle Int* 2018;39:458–62.
- [36] Berlet GC, Hyer CF, Lee TH, Philbin TM, Hartman JF, Wright ML. Interpositional arthroplasty of the first MTP joint using a regenerative tissue matrix for the treatment of advanced hallux rigidus. *Foot Ankle Int* 2008;29:10–21.
- [37] Hyer CF, Granata JD, Berlet GC, Lee TH. Interpositional arthroplasty of the first metatarsophalangeal joint using a regenerative tissue matrix for the treatment of advanced hallux rigidus: 5-year case series follow-up. *Foot Ankle Spec* 2012;5:249–52.
- [38] Goldberg A, Singh D, Glazebrook M, Blundell CM, De Vries G, Le IL, et al. Association between patient factors and outcome of synthetic cartilage implant hemiarthroplasty vs first metatarsophalangeal joint arthrodesis in advanced hallux rigidus. *Foot Ankle Int* 2017;38:1199–206.
- [39] Daniels TR, Younger AS, Penner MJ, Wing KJ, Miniaci-Coxhead SL, Pinsker E, et al. Midterm outcomes of polyvinyl alcohol hydrogel hemiarthroplasty of the first metatarsophalangeal joint in advanced hallux rigidus. *Foot Ankle Int* 2017;38:243–7.
- [40] Baumhauer JF, Singh D, Glazebrook M, Blundell CM, De Vries G, Le IL, et al. Correlation of hallux rigidus grade with motion, vas pain, intraoperative cartilage loss, and treatment success for first MTP joint arthrodesis and synthetic cartilage implant. *Foot Ankle Int* 2017;38:1175–82.
- [41] Baumhauer JF, Singh D, Glazebrook M, Blundell C, De Vries G, Le IL, et al. Prospective, randomized, multi-centered clinical trial assessing safety and efficacy of a synthetic cartilage implant versus first metatarsophalangeal arthrodesis in advanced hallux rigidus. *Foot Ankle Int* 2016;37:457–69.
- [42] Landis JR, Koch GG. The measurement of observer agreement for categorical data. *Biometrics* 1977;33:159–74.
- [43] Fraser EJ, Sullivan M, Panti JP, Rositano P, Walton J, Fung S. Computed tomography measurements of the lesser metatarsal heads: anatomic considerations for surgeons performing distal metatarsal osteotomies. *Foot Ankle Surg* 2017;23:230–5.
- [44] Couqueberg Y, Augoyard R, Augoyard M, Berry-Kromer V, Bouby C, Girod L. A statistical study of metatarsal anatomy: toward the design of wide-range prosthetic solutions. *Foot Ankle Spec* 2018;11:277–87.
- [45] Galli MM, Brigido SA, Protzman NM. Pinning across the metatarsophalangeal joint for hammertoe correction: where are we aiming and what is the damage to the metatarsal articular surface? *J Foot Ankle Surg* 2014;53:405–10.
- [46] el-Tayeb HM. Freiberg's infraction: a new surgical procedure. *J Foot Ankle Surg* 1998;37:23–7 discussion 79.