

Technical Note

Arthroscopic Transfer of the Long Head Biceps to the Conjoint Tendon

Nikhil N. Verma, M.D., Mark Drakos, M.D., and Stephen J. O'Brien, M.D.

Abstract: Pathology of the biceps tendon is often a factor in the etiology of shoulder pain. However, diagnosis and treatment of such pathology remains controversial. When conservative management fails to relieve symptoms, surgical options include tenotomy or tenodesis. Tenotomy has provided excellent results with regard to local pain relief, but a potential cosmetic deformity and occasional painful cramping are common in younger patients. Tenodesis has also had high failure rates resulting from persistent local pain. We have used an all-arthroscopic technique for transfer of the long-head biceps to the conjoint tendon instead of traditional tenodesis. We believe that this transfer more closely recreates the normal axis of the biceps muscle and may offer improved results over conventional tenodesis. **Key Words:** Shoulder arthroscopy—Biceps tendonitis—Arthroscopic transfer.

The knowledge of the biceps tendon as a potential source of pain in the shoulder has been longstanding. However, the diagnosis and treatment of biceps tendon pathology still remains controversial. Conservative management includes activity modification, physical therapy, local steroid injections, and oral anti-inflammatory medications. Although reports of the results of conservative management are limited, patients with a component of biceps tenosynovitis may be more resistant to treatment than standard subacromial impingement.¹ Furthermore, patients with mechanical symptoms caused by biceps pathology rarely respond to conservative treatment.

When conservative management fails, surgical options include tenotomy or tenodesis. Recently, tenotomy has been reported to provide reliable pain relief, but complications including cosmetic deformity and muscle spasm are common in younger patients.²⁻⁴ In terms of tenodesis, reports in the literature of the use of contemporary techniques are limited. However, earlier reports have indicated a fairly high failure rate, especially when tenodesis is performed without concomitant subacromial decompression.⁵⁻⁷ More recently, the senior author (S.J.O.) has developed an arthroscopic technique for transfer of the long head biceps tendon to the conjoint tendon as a method of tenodesis.

From the Sports Medicine and Shoulder Service, The Hospital for Special Surgery, Affiliated with the New York Hospital, Cornell University Medical Center, New York, New York, U.S.A.

Address correspondence and reprint requests to Stephen J. O'Brien, M.D., The Hospital for Special Surgery, 535 E. 70th St, New York, NY 10021, U.S.A. E-mail: ObrienS@hss.edu

© 2005 by the Arthroscopy Association of North America

Cite this article as: Verma NN, Drakos M, O'Brien SJ. Arthroscopic transfer of the long head biceps to the conjoint tendon. Arthroscopy 2005;21:764.e1-764.e5 [doi:10.1016/j.arthro.2005.03.032].

0749-8063/05/2106-4264\$30.00/0

doi:10.1016/j.arthro.2005.03.032

SURGICAL TECHNIQUE

The patient is placed in the beach-chair position on the operating room table. Preoperatively, a thorough examination under anesthesia should be performed to evaluate passive range of motion and potential instability. A standard posterior viewing portal is then established and the arthroscope is introduced. Diagnostic arthroscopy is performed and an accessory portal in the anterior triangle is established.⁸

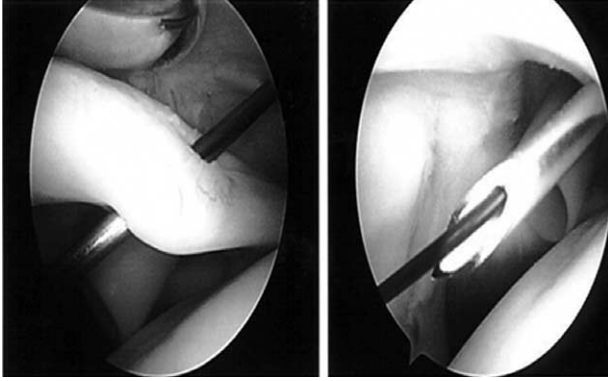


FIGURE 1. The biceps tendon is tagged arthroscopically using a spinal needle placed through the substance of the tendon as a passing device for a No. 0 PDS suture.

At this point, the biceps tendon is inspected, including the anchor to the superior labrum. A probe is used to displace the tendon inferiorly to allow visualization of the entire intra-articular portion. Using this information combined with the preoperative physical examination findings, a decision to proceed with the transfer can be made.

Once a decision to proceed with the transfer has been made, the biceps tendon is tagged with No. 0 PDS sutures (Fig 1). This is accomplished by placing a spinal needle percutaneously through the rotator interval using a starting point just off the anterolateral corner of the acromion. The needle is then passed through the biceps tendon, and the PDS suture is passed through the needle and brought out through an accessory posterior portal. This keeps the sutures in the joint for the time being and allows for simple suture management after release. In this manner, 2 or 3 No. 0 PDS sutures can be placed through the tendon for later use as a tagging stitch.

Once the long head biceps tendon has been tagged, it is released from its origin on the superior labrum (Fig 2). This can be accomplished using an arthroscopic basket or scissors or using a radiofrequency device. At this point the remaining stump is debrided using a mechanical shaver and any remaining intra-articular pathology is addressed.

A thorough subacromial decompression is performed using a combination of a mechanical shaver and a radiofrequency device to allow visualization of the subacromial space and of the bicipital groove laterally. An acromioplasty can be performed if indicated. The coracoacromial ligament is then taken down as necessary to allow access and visualization of the conjoint tendon medially. Next, the subdeltoid

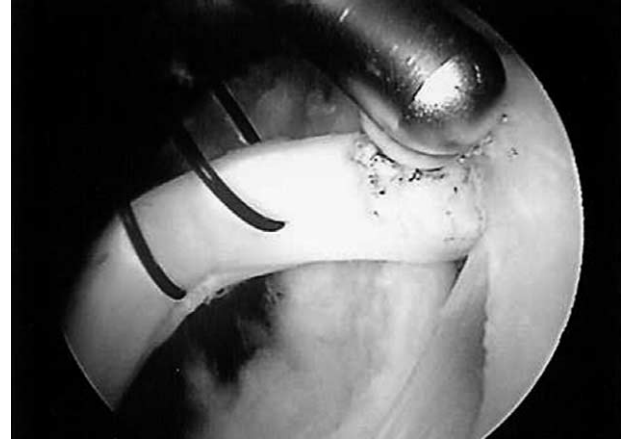


FIGURE 2. Arthroscopic view of the long head biceps tendon with No. 0 PDS tagging sutures in place. The tendon is being released from the biceps anchor using a radiofrequency device.

space is carefully cleared to expose the conjoint tendon medially and short head of the biceps (Fig 3). This space is then further cleared down inferiorly to the pectoralis major muscle and then laterally to the pectoralis major tendon, which will insert lateral to the biceps tendon. A spinal needle is then used to localize a superior, anterolateral portal in line with the bicipital groove. This portal is created using a knife while viewing from the posterior intra-articular portal. At this point, the arthroscope is advanced to view down the bicipital sleeve to allow as much release of the bicipital sleeve as possible from the superior, anterolateral portal with an arthroscopic scissors or arthroscopic banana blade. Arthroscopic cautery with a bi-

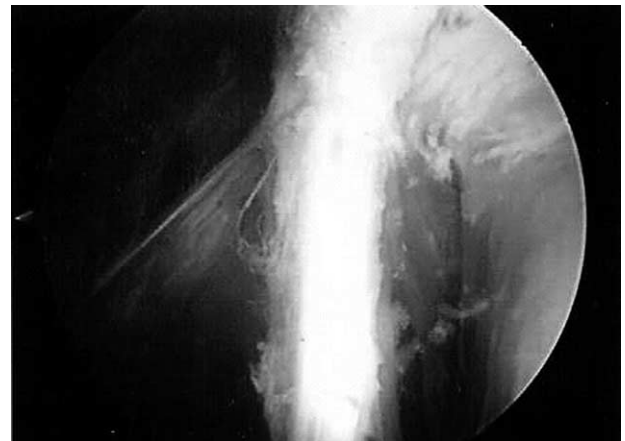

FIGURE 3. Arthroscopic view of the conjoint tendon as visualized from the anterolateral portal.

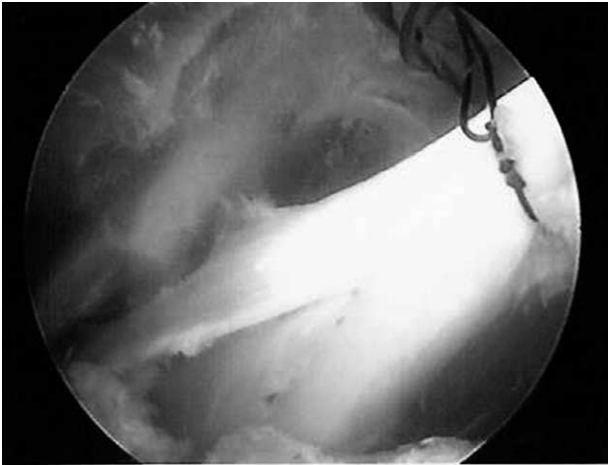

FIGURE 4. Arthroscopic view of the long head biceps tendon being tensioned alongside the conjoint tendon.

polar radiofrequency device (Arthrocare, Sunnyvale, CA) is used to coagulate any local bleeding.

Spinal needle localization is then used to establish 2 additional portals. The first is placed inferiorly in line with the intersection of the bicipital groove and the pectoralis major tendon. This allows viewing from “below up” to continue the release of the bicipital hood from the anterolateral portal. The second portal is a mid-anterolateral portal that is lateral to the bicipital groove approximately halfway between the superior, anterolateral portal and the inferior portal. This portal can allow for visualization or for passage of a blunt retractor to improve exposure of the subdeltoid space. This portal can be critical for visualization and retraction.

While looking from the mid-anterolateral portal, a spinal needle is then passed from above the coracoid in line with the conjoint tendon and then a stab wound is made to allow a blunt suture-retrieving instrument to be passed to retrieve the biceps tagging sutures. The final portal is placed directly anterior to the proximal portion of the conjoint tendon to allow for the suturing of the long head of the biceps to the conjoint tendon. A cannula is placed in this portal for later suturing of the repair. At this point, the biceps tendon and tagging sutures are identified and the sutures are brought out from the superior coracoid portal to allow for tensioning of the transfer (Fig 4). While viewing from the superior anterolateral portal, the overlying pectoralis major tendon is visualized, and the biceps should be released to this level.

Once the tendon is completely released, it is pulled in line with the conjoint tendon. The elbow is flexed to

90° and the transfer is tensioned by pulling on the tagging sutures until the biceps is slightly bowstrung. A looped suture retriever (“loopie”) is then passed from 1 of the lateral portals reducing the long head of the biceps to the conjoint while the superior tensioning is held, and the reduction is held in place by an assistant. A spectrum or other suture-passing device is then used to pass a loop-ended No. 0 PDS suture through the biceps and the conjoint tendon. The loop is passed through 1 of the lateral portals and No. 2 Tevdek suture (Deknatel DSP, Fall River, MA) is shuttled back through the anterior coracoid cannula. The other end of the No. 2 Tevdek is then retrieved out through the coracoid cannula and the long head of the biceps is then sutured in place using arthroscopic knot-tying techniques. In this manner, 3 or 4 sutures can be placed to secure the transferred long head biceps tendon. Finally, the excess portion of tendon is cut and removed along with the tagging sutures, thus completing the transfer (Fig 5).

The elbow is then put through a full range of motion while visualizing the repair. Although this tensioning technique was empirically derived, it appears to give a repair that is isometric with little to no tension with elbow motion. The senior author has performed approximately 30 of these transfers to date. We had the occasion to perform a second arthroscopy on 2 transfers that we had performed using an arthroscopic-assisted technique (before this current technique) for removal of scar tissue. In both cases, there was complete healing of the transfer and no Popeye sign (Fig 6). We have had no cases of painful scarring to date with this current all-arthroscopic technique.

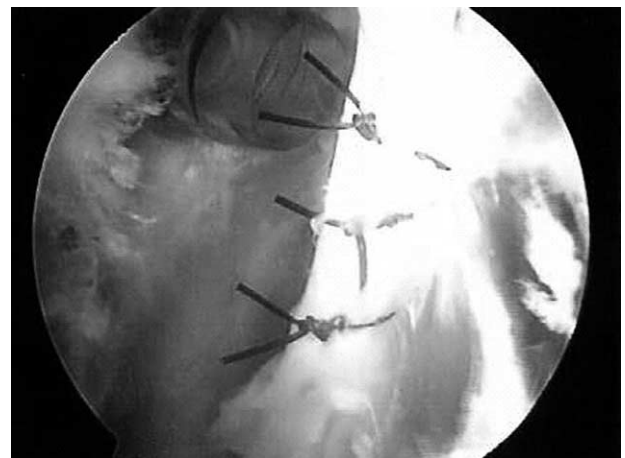

FIGURE 5. Arthroscopic view of the completed repair.

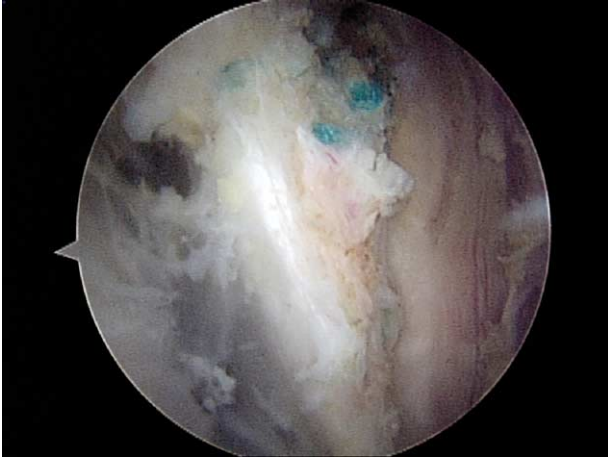

FIGURE 6. Arthroscopic view of a completed repair at the 2-year follow-up. The long head biceps has completely healed to the conjoint tendon.

Postoperative Protocol

Patients are placed in a sling full time for the first 3 days, and then only at night and in crowds for the remainder of the first 2 weeks. They are allowed and encouraged to come out of the sling for active and active-assisted shoulder and elbow range of motion immediately postoperatively. They are not allowed to lift anything heavier than a pen, knife, fork, or spoon. Formal physical therapy is started at the 2-week mark at the first postoperative visit. They are allowed complete activities of daily living at 4 weeks, full throwing and swimming as tolerated at 3 months, and unrestricted activity including lifting at 4 to 5 months.

Complications

One patient partially ruptured his repair in the first 2 weeks when he tried to take off his socks with difficulty with his newly operated arm. We have added this as something not to try postoperatively.

DISCUSSION

The long head biceps tendon continues to play a controversial role in shoulder surgery. In fact, its exact role in shoulder kinematics has not yet been elucidated. Some authors believe that the tendon may play an important role in shoulder stability.^{9,10} Others believe that the tendon is clinically insignificant, serving only as a vestigial structure.¹¹⁻¹³ Despite this controversy, it is commonly accepted that the biceps tendon

can play an important role in shoulder pathology and serve as a major pain generator within the shoulder.

The surgical management of biceps tendon pathology remains equally controversial. Current surgical options include tenotomy, tenodesis, or transfer. Recently, the results of tenotomy have been reported. These studies have found that tenotomy provides reliable pain relief with the shoulder at rest.²⁻⁴ However, in younger patients, complications including cosmetic Popeye deformity and spasm of the biceps muscle belly were not uncommon.

Tenodesis techniques have traditionally involved bony fixation of the tendon to the proximal humerus through an open or arthroscopic technique. The tendon can be fixed proximally in the bicipital groove, or more distally under the pectoralis major tendon. Furthermore, multiple techniques of fixation can be used including bone tunnels, bone anchors, staples, or interference screws. Earlier techniques of transposition of the long head biceps to the conjoint tendon have involved direct tenodesis to the coracoid process.^{6,7} To our knowledge, soft-tissue transfer to the conjoint tendon has not been described. Furthermore, there are no reports in the current literature regarding the results of one technique compared with another.

The overall results of biceps tenodesis reported in the literature are quite variable. Dines et al.⁷ reported on 20 shoulders, 17 of which underwent tenodesis and 3 underwent open transposition of the tendon to the coracoid for symptomatic long head biceps lesions. Of these, there were 6 failures that required revision surgery. No distinction was made between patients who underwent tenodesis or transposition. The authors concluded that persistent impingement played a key role in the cases that failed and that this pathology must be carefully considered and addressed at the time of surgery.

Similarly, Becker and Cofield⁵ evaluated 50 shoulders at an average follow-up of 13 years. Satisfactory results were noted in only about 50% of patients at long-term follow-up. The authors again concluded that biceps tenosynovitis is only rarely present in isolation and should only be considered as part of the spectrum of shoulder pain. In all cases, underlying rotator cuff disease must be considered.

Some have noted favorable results with biceps tenodesis. Post and Benca⁶ reported on 17 patients at 42-month follow-up; 13 patients underwent tenodesis and 4 patients underwent open transfer to the coracoid. Overall, 94% of patients had good or excellent results at final follow-up. More recently, Weber and Kauffman¹⁴ presented the results of 81 patients using

a mini-open subpectoral tenodesis technique. At mean follow-up of 6.7 years, postoperative UCLA scores averaged 31.4. The authors concluded that this technique had acceptable long-term outcomes without the complexity associated with all-arthroscopic techniques.

In our experience, we have found traditional tenodesis to be associated with a fairly high complication rate. Furthermore, we have had a number of patients who required takedown of the tenodesis because of persistent pain or the development of regional pain syndrome. We believe that the arthroscopic transfer described earlier may provide improved results over traditional bony tenodesis for multiple reasons. First, transfer more closely reproduces the native axis of pull of the biceps muscle and allows the long head and short head to share load. Second, the transfer allows for soft-tissue healing, which may be more favorable than soft tissue to bone as it recreates the normal bungee effect of the superior labrum/biceps anchor complex. Finally, this technique provides the surgeon with direct visualization during tensioning and suturing to help prevent overtensioning of the tendon.

Other advantages of this technique include its simplicity. The technique is performed in an avascular plane without the use of implants, and adds only 10 to 15 minutes to the operative time once the subacromial decompression is completed. Furthermore, the technique will help avoid the cosmetic deformity or muscle cramping that may occur with tenotomy alone.

Potential complications with this technique are limited. First, when releasing the long head biceps from the bicipital groove, care must be taken to release the hood over the tendon in its entirety; however, the surgeon must be careful to avoid injury to the overlying pectoralis major tendon. If visualization is impaired, a retractor can be placed across the overlying deltoid through a small stab incision to retract it anteriorly and improve the space. Failure to release the hood will result in an acute angle as the tendon is transferred to the conjoint tendon. Second, the tendon should be placed laterally along the conjoint tendon to avoid coracoid impingement that could occur with posterior placement. Finally, care must be taken to avoid injury to the musculocutaneous nerve. The nerve usually enters the coracobrachialis an average of 5 cm distal to the coracoid process, but may have a more proximal site of insertion in 5% of patients.¹⁵

Diagnosis and treatment of long head biceps tendon pathology remain difficult and controversial. The di-

agnosis of biceps tendon pathology can be troublesome and controversy exists over definitive treatment. Conservative management should be tried initially in most cases, including physical therapy and anti-inflammatory medications. When this fails, surgical options include debridement, repair, tenotomy, or tenodesis. Arthroscopic transfer to the conjoint tendon provides a simple technique for all-arthroscopic tenodesis and may provide improved results over conventional techniques.

Acknowledgment: The authors thank Anastasios Vassiliou, STII, and Ronald M. Selby, M.D., for their assistance with the development of this technique.

REFERENCES

1. Neviasser RJ. Lesions of the biceps and tendonitis of the shoulder. *Orthop Clin North Am* 1980;11:343-348.
2. Gill TJ, McIrvine E, Mair SD, Hawkins RJ. Results of biceps tenotomy for treatment of pathology of the long head of the biceps brachii. *J Shoulder Elbow Surg* 2001;10:247-249.
3. Huffman GR, Wolf EM. Arthroscopic biceps tenotomy: Results in patients with symptomatic degeneration of the long head of the biceps brachii tendon. *Arthroscopy* 2003;19:5 (suppl 2).
4. Kelly AM, Drakos MC, Fealy S, Taylor SA, O'Brien SJ. Arthroscopic release of the long head of the biceps tendon: Functional outcome and clinical results. *Am J Sports Med* 2005;33:208-213.
5. Becker DA, Cofield RH. Tenodesis of the long head of the biceps brachii for chronic bicipital tendonitis: Long-term results. *J Bone Joint Surg Am* 1989;71:376-381.
6. Post M, Benca P. Primary tendonitis of the long head of the biceps. *Clin Orthop Rel Res* 1989;246:117-125.
7. Dines D, Warren RF, Inglis AE. Surgical treatment of the long head of the biceps. *Clin Orthop Rel Res* 1982;164:165-171.
8. Andrews JR, Carson WG, Ortega K. Arthroscopy of the shoulder: technique and normal anatomy. *Am J Sports Med* 1984; 12:1-7.
9. Kumar VP, Satku K, Balasubramaniam P. The role of the long head of biceps brachii in the stabilization of the head of the humerus. *Clinic Orthop Rel Res* 1989;244:172-175.
10. Rodosky MW, Harner CD, Fu FH. The role of the long head of the biceps muscle and superior glenoid labrum in anterior stability of the shoulder. *Am J Sports Med* 1994;22:120-121.
11. Lippmann RK. Bicipital tenosynovitis. *N Y State J Med* 1944; Oct:2235-2241.
12. Levy AS, Kelly B, Lintner S, Speer KP. The function of the long head of the biceps at the shoulder: An EMG analysis. *J Shoulder Elbow Surg* 2001;10:250-255.
13. Yamaguchi K, Riew KD, Galatz LM, Syme JA, Neviasser RJ. Biceps activity during shoulder motion: An electromyographic analysis. *Clin Orthop* 1997;336:122-129.
14. Weber SC, Kauffman J. Subpectoral biceps tenodesis in the management of tears of the long head of the biceps: Long term follow-up. *Arthroscopy* 2003;19:6 (suppl 2).
15. Bach BR Jr, O'Brien SJ, Warren RF, Leighton M. An unusual complication of the Bristow procedure. *J Bone Joint Surg Am* 1988;70:458-460.